Ann Surg Oncol
https://doi.org/10.1245/s10434-020-08514-6

Annals of
SURGICAL ONCOLOGY
OFFICIAL JOURNAL OF THE SOCIETY OF SURGICAL ONCOLOGY

ORIGINAL ARTICLE – HEPATOBILIARY TUMORS

Robotic Resection of Hilar Cholangiocarcinoma

Marcel Autran Machado, MD, FACS[1,2], Bruno V. Mattos, MD[2], Murillo Macedo Lobo Filho, MD[2], and Fabio Makdissi, MD[2]

[1]Department of Surgery, University of São Paulo, São Paulo, Brazil; [2]Nove de Julho Hospital, São Paulo, Brazil

ABSTRACT

Background. Hilar cholangiocarcinoma is the most common malignant neoplasm of the biliary tract. Surgical resection is the only curative modality of treatment. The aim of this video is to present a robotic left hepatectomy extended to caudate lobe, combined with bile duct resection, lymphadenectomy, and Roux-en-Y biliary reconstruction.

Methods. A 76-year-old female presented with progressive jaundice due to hilar cholangiocarcinoma. She underwent chemoradiation and after 5 months of treatment was referred for second opinion; imaging reevaluation showed objective response and no arterial invasion. Multidisciplinary team decided for radical treatment, which consisted in robotic left hepatectomy, caudate lobe resection, resection of bile duct, lymphadenectomy, and hepaticojejunostomy.

Results. Operative time was 8 h. Estimated blood loss was 740 mL (received 2 U). The patient's recovery was complicated by drainage clogging resulting in fever and perihepatic fluid collection, successfully treated by change of drainage. Pathology confirmed cholangiocarcinoma with free surgical margins (T1aN0). The patient is well, with no signs of disease 5 months after the procedure.

Conclusions. Robotic resection of hilar cholangiocarcinoma is feasible and safe. The robotic approach has some technical advantages over laparoscopic approach. This video may help oncological surgeons to perform this complex procedure.

Electronic supplementary material The online version of this article (https://doi.org/10.1245/s10434-020-08514-6) contains supplementary material, which is available to authorized users.

First Received: 8 February 2020

M. A. Machado, MD, FACS
e-mail: dr@drmarcel.com.br

Published online: 03 May 2020

Hilar cholangiocarcinoma is the most common malignant neoplasm of the biliary tract. Surgical resection is the only curative modality of treatment. Liver resection combined with complete extrahepatic bile duct resection, lymphadenectomy, and biliary reconstruction represents the current standard surgical treatment.[1, 2] Minimally invasive liver resection is a feasible and safe technique and has been used to treat several types of liver neoplasms.[3, 4] Technical limitations and oncologic concerns have limited the adoption of minimally invasive techniques for the treatment of hilar cholangiocarcinoma.[5-8] Since 2012, we have been using this approach.[9, 10] The aim of this video is to present a robotic left hepatectomy extended to caudate lobe, combined with bile duct resection, lymphadenectomy, and Roux-en-Y biliary reconstruction.

METHODS

A 76-year-old female presented with progressive jaundice. Past medical history consisted of obesity and gastroesophageal reflux. She underwent laparoscopic cholecystectomy in 2008. Imaging showed intrahepatic bile duct dilation and a 1.8-cm tumor in the confluence of hepatic ducts (Fig. 1a, b). She was seen in another service but considered not resectable due to arterial invasion (Fig. 1c, d). Endoscopic retrograde cholangiopancreatography (ERCP) was performed, and an endoprosthesis was inserted in the right hepatic duct. She underwent chemoradiation, and after 5 months of treatment was sent home for observation. At this time, she was referred for second opinion and imaging reevaluation was performed. Computed tomography (CT) scan showed objective response, while neither portal nor arterial invasion was seen. Multidisciplinary team decided for radical surgical

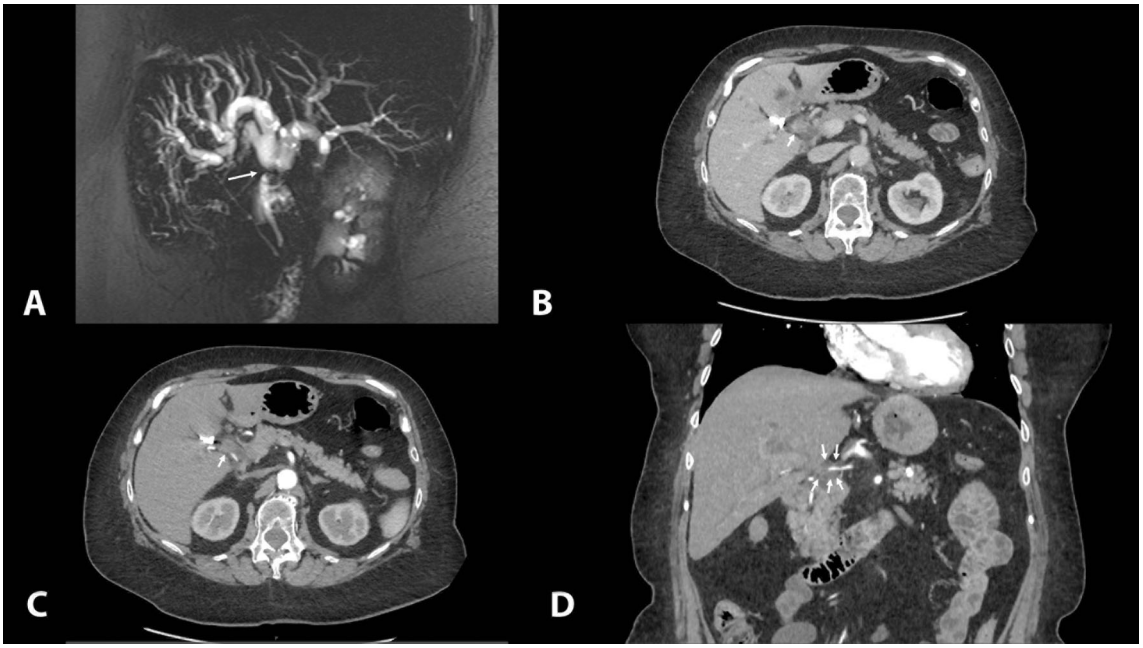

FIG. 1 Hilar cholangiocarcinoma. Imaging studies before neoadjuvant chemotherapy. **a** Magnetic resonance imaging (MRI) cholangiogram shows an interruption at the level of hilar bifurcation (arrow). Note that right anterior and posterior section bile duct bifurcation occurs about 2 cm above main bifurcation. **b** CT scan shows a 1.8-cm mass in the hepatic hilum (arrow). **c** CT scan shows close contact of this mass with the right hepatic artery (arrow). **d** CT scan (coronal view) shows close contact of this mass with the right hepatic artery (arrows)

treatment. Left hepatectomy (including caudate lobe), complete resection of bile duct, lymphadenectomy, and Roux-en-Y hepaticojejunostomy was the procedure of choice due to the type of hilar cholangiocarcinoma. Robotic approach was proposed, and consent was obtained. This study was approved by the review board of the Department of Surgery of our institution.

SURGICAL TECHNIQUE

Patient Positioning and Port Placement

The patient was placed in supine position and 30° reverse Trendelenburg position. Robotic surgery was performed using the da Vinci Si robotic platform (Intuitive Surgical Inc., Sunnyvale, CA). This technique used five trocars (Fig. 2). Pneumoperitoneum was created using an open technique in the infraumbilical port (A in Fig. 2). The pneumoperitoneum was established at 14 mmHg. The remaining trocars were inserted under direct vision (Fig. 2). For this technique, the surgeon is seated at the robotic console and the assistant surgeon stands on the patient's left side. The assistant surgeon performs retraction, suction, clipping, and stapling, and changes the robotic instruments.

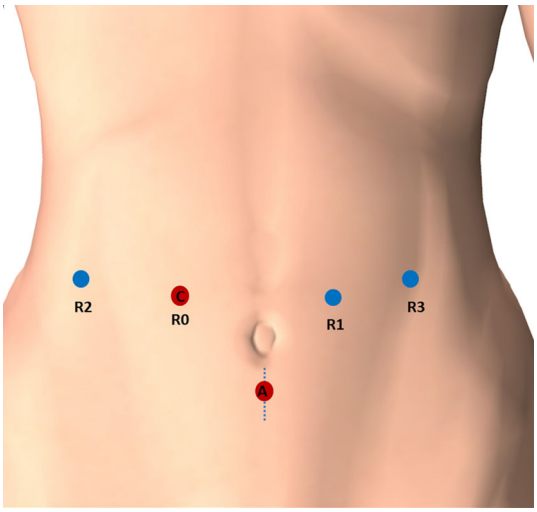

FIG. 2 Robotic resection of hilar cholangiocarcinoma. Schematic drawing showing incisions for the robotic camera (R0), robotic arms (R1–R3), the auxiliary port (A), and extension of infraumbilical port (dotted line) used for retrieval of surgical specimen

Hilar Dissection and Lymphadenectomy

The operation began with division of adhesion from previous cholecystectomy. Dissection along the common hepatic artery with removal of lymph nodes was performed until complete skeletonization of the celiac trunk, left gastric, splenic, and hepatic arteries (Fig. 3a). Hilar

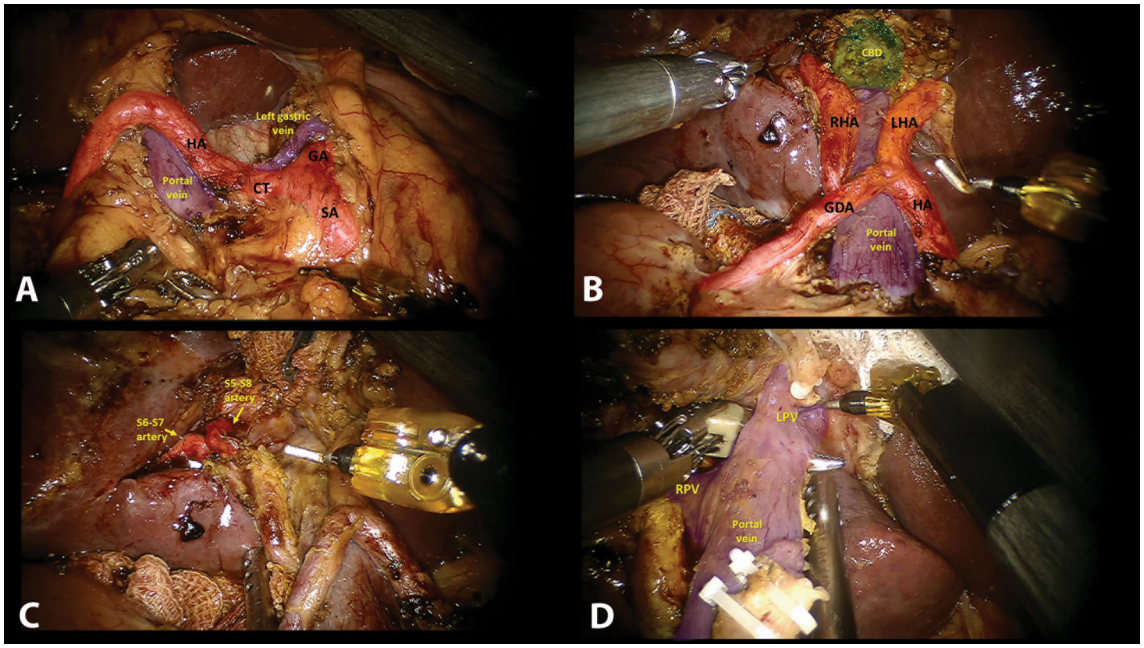

FIG. 3 Robotic resection of hilar cholangiocarcinoma. **a** Intraoperative view after celiac trunk (CT) lymphadenectomy. *GA* left gastric artery, *SA* splenic artery, *HA* common hepatic artery. **b** Intraoperative view after hilar lymphadenectomy. *GDA* gastroduodenal artery, *RHA* right hepatic artery, *LHA* left hepatic artery, *HA* common hepatic artery, *CBD* common hepatic duct. **c** Intraoperative view shows dissection and identification of right anterior (S5–S8) and right posterior (S6–S7) arteries. **d** Intraoperative view shows complete dissection of main portal vein and right portal vein (RPV) and encircling of left portal vein (LPV)

dissection continued towards portal vein and common bile duct. Distal common bile duct was divided with scissors, and endoprosthesis was removed. Frozen-section biopsy of the distal bile duct was negative. Bile duct was sutured distally and proximally to avoid bile spilling. Hilar lymphadenectomy was then performed during hilar dissection (Fig. 3b). A known replaced right hepatic artery was identified and preserved. Right hepatic artery was dissected until its first bifurcation (posterior and anterior sector) and was free of tumor (Fig. 3c). Portal vein was dissected until bifurcation and free of tumor. Right hepatic duct was dissected and divided. Frozen-section biopsy of the proximal bile duct was negative. We then proceeded with inflow control of the left liver. Left hepatic artery was divided between Hem-o-loks. Left portal vein was encircled and controlled with ligature and Hem-o-lok (Fig. 3d). Ligature was reinforced with 4-0 Prolene suture. Fluorescence imaging after injection of indocyanine green showed complete devascularization of the left liver.

Left Hepatectomy with Caudate Lobe Resection

Left liver was fully mobilized by dividing left triangular, coronary, round, and falciform ligaments. Caudate lobe was carefully detached from inferior vena cava. Larger venous branches were controlled with Hem-o-loks (Fig. 4a). Left hepatic vein was identified and encircled with robotic instrument (Fig. 4b). Left hepatic vein was then divided with ligature and Hem-o-lok. Ligature was reinforced with 4-0 Prolene suture. Future line of transection was marked with cautery along ischemic area, and its margin checked with fluorescence imaging. Liver parenchyma was then divided using a combination of bipolar forceps and scissors under saline irrigation. Left hepatectomy including the caudate lobe was completed, and raw area was checked for bleeding and bile leakage (Fig. 4c).

Roux-en-Y Biliary Reconstruction

The jejunum was divided with stapler 30 cm from the Treitz angle. The Roux-en-Y loop was constructed with laterolateral jejunojejunostomy using a stapler. The opening was closed in a two-layer running suture, and jejunal loop was brought for hepatojejunostomy in transmesocolic fashion. Right bile duct inspection showed that it was divided immediately after posterior and anterior sector bifurcation, therefore its reconstruction could be performed in a single anastomosis. Hepatojejunostomy was performed with 5-0 running absorbable suture (Fig. 4d). The raw liver area was then checked for bleeding and bile leakage. The abdominal cavity was drained, and the operation was finished with removal of the surgical specimen through the extension of the infraumbilical incision.

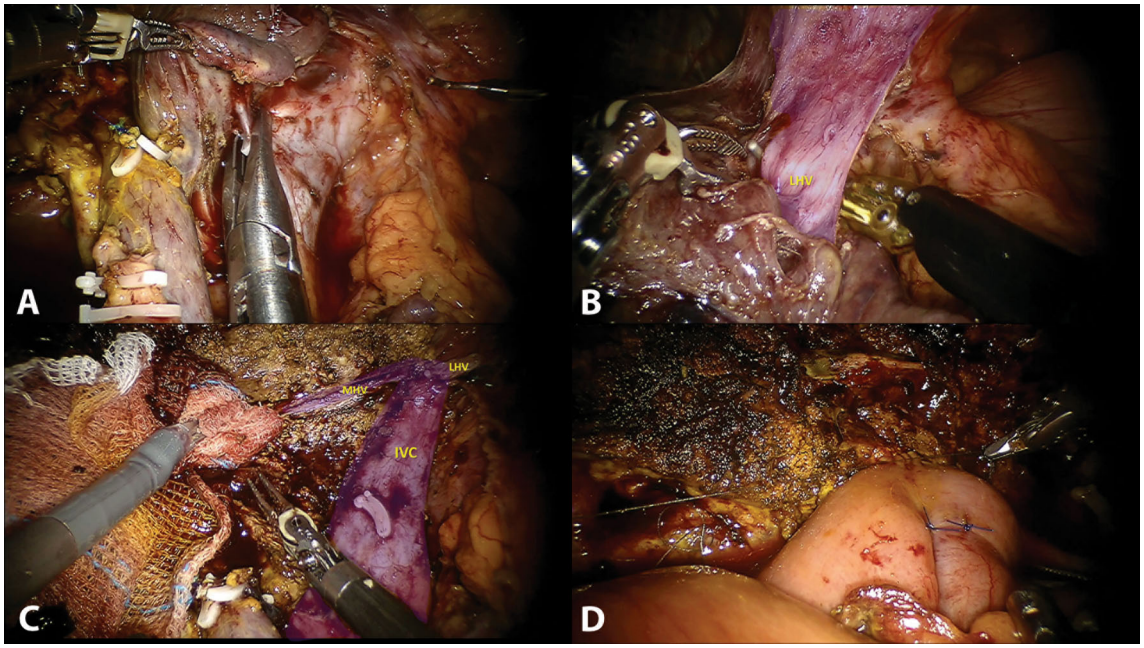

FIG. 4 Robotic resection of hilar cholangiocarcinoma. **a** Caudate lobe is carefully detached from inferior vena cava. Intraoperative view shows control of a larger venous branch. **b** Intraoperative view. Left hepatic vein is identified and encircled with robotic instrument. **c** Intraoperative view after left hepatectomy extended to caudate lobe shows the retrohepatic inferior vena cava (IVC) completely dissected, the middle hepatic vein (MHV) exposed, and the left hepatic vein (LHV) ligated. **d** Intraoperative view shows completion of Roux-en-Y hepaticojejunostomy

RESULTS

Operative time was 8 h. Estimated blood loss was 740 mL (received 2 U). The patient's recovery was complicated by drainage clogging resulting in fever and perihepatic fluid collection, successfully treated by change of drainage. Pathology confirmed cholangiocarcinoma with free surgical margins (T1aN0). The patient is well, with no signs of disease 5 months after the procedure.

DISCUSSION

The first minimally invasive procedure for hilar cholangiocarcinoma was published in 2010, and it was done by robotic approach.[8] In 2012, we described the first laparoscopic procedure for hilar cholangiocarcinoma.[9] Since then, only a few cases have been reported.[11-14] In a recent systematic review of the literature on this subject, only 29 cases were found.[7] Minimally invasive resection of hilar cholangiocarcinoma, in accordance with this review, appears to be feasible and safe, but the number of studies is small. The complexity of hilar dissection, hilar lymphadenectomy, and biliary reconstruction is a limiting factor that restricts the development of laparoscopic approach. Therefore, interest in using robotic approach for this disease is increasing. Whilst writing this manuscript, the largest series of robotic radical surgery for hilar cholangiocarcinoma was published in China.[15] According to that study, robotic approach is technically achievable in selected patients, and enthusiasm for robotic procedures in hilar cholangiocarcinoma should be encouraged.[15] However, there is a lack of detailed technical description or video availability of this complex operation.

Since 2018, all our minimally invasive liver surgeries have been performed using the robotic platform. Our experience with this new system has increased, and so have the indications for more complex cases using the robotic approach.[16-18] Biliary surgery was generally performed with open techniques and was considered a relative contraindication to minimally invasive techniques until recently. Complex Roux-en-Y hepaticojejunostomies with small or multiple bile ducts were rarely described in minimally invasive setting. The robotic approach, with its added degrees of freedom and stability of the robotic platform, may offer options for minimally invasive performance of complex hepaticojejunostomy that can overcome these limitations. The da Vinci robot provides $\times$ 20 magnified three-dimensional (3D) vision, improving the precision of hilar dissection and allowing anastomosis sutures at difficult angles with the nondominant hand, when necessary.[17]

Procedures that require excellent accuracy and dexterity are the best candidates for robotic surgery. Vascular structures, such as portal vein, hepatic artery, and hepatic

veins, are magnified in robotic vision. The magnified vision camera can expose the anatomic structure of the hilum. Excellent visualization is key to the control of the intraoperative bleeding caused by mobilization of the liver and during manipulation of the caudate lobe. Indeed, radical treatment of hilar cholangiocarcinoma, which includes major hepatectomy with caudate lobe removal, extrahepatic bile duct resection, lymphadenectomy, and Roux-en-Y hepaticojejunostomy, may be an excellent indication for robotic approach if minimally invasive surgery is advised.

R0 resection is the most important factor for long-term survival. In our patient, R0 resection could be obtained with radical resection. Frozen-section biopsy was crucial to ascertain negative bile duct margins, especially after neoadjuvant chemoradiation. Right liver resection is usually the procedure of choice due to its anatomic advantages over left hepatectomy. The remnant left hepatic duct is longer than the right and less prone to anatomic variations, thus increasing the risk of positive margin if left hepatectomy is performed. In our patient, there was a dominance of left hepatic duct invasion and only the right bile duct was drained, making her unsuitable for right liver resection. Moreover, the right hepatic bile duct was exceptionally long, and anterior and posterior sector bifurcation was about 2 cm above main bifurcation. These anatomical particularities allowed R0 resection with left liver resection.

CONCLUSIONS

Robotic resection of hilar cholangiocarcinoma is feasible and safe. The robotic approach may have some advantages over laparoscopic and open approach. This video may help oncological surgeons to perform this complex procedure.

DISCLOSURES The authors declare no conflicts of interest.

REFERENCES

1. Mansour JC, Aloia TA, Crane CH, et al. Hilar cholangiocarcinoma: expert consensus statement. *HPB (Oxford)*. 2015;17:691–99.
2. Poruk KE, Pawlik TM, Weiss MJ. Perioperative management of hilar cholangiocarcinoma. *J Gastrointest Surg*. 2015;19:1889–99.
3. Ciria R, Cherqui D, Geller DA, et al. Comparative short-term benefits of laparoscopic liver resection: 9000 cases and climbing. *Ann Surg*. 2016;263:761–77
4. Tsung A, Geller DA, Sukato DC, et al. Robotic versus laparoscopic hepatectomy: a matched comparison. *Ann Surg*. 2014;259:549–55.
5. Wakabayashi G, Cherqui D, Geller DA, et al. Recommendations for laparoscopic liver resection: a report from the second international consensus conference held in Morioka. *Ann Surg* 2015;261:619–29.
6. Liu R, Wakabayashi G, Kim H-J, et al. International consensus statement on robotic hepatectomy surgery in 2018. *World J Gastroenterol* 2019;25:1432–44.
7. Shiraiwa DK, Carvalho PFDC, Maeda CT, et al. The role of minimally invasive hepatectomy for hilar and intrahepatic cholangiocarcinoma: A systematic review of the literature. *J Surg Oncol* 2020;121:863–72.
8. Giulianotti PC, Sbrana F, Bianco FM, Addeo P. Robot-assisted laparoscopic extended right hepatectomy with biliary reconstruction. *J Laparoendosc Adv Surg Technol A* 2010;20:159–63.
9. Machado MA, Makdissi FF, Surjan RC, Mochizuki M. Laparoscopic resection of hilar cholangiocarcinoma. *J Laparoendosc Adv Surg Technol A*. 2012;22:954–56.
10. Machado MA, Makdissi FF, Surjan RC. Totally laparoscopic right hepatectomy with Roux-en-Y hepaticojejunostomy for right-sided intraductal papillary mucinous neoplasm of the bile duct. *Ann Surg Oncol.* 2014;21:1841–43.
11. Hu HJ, Wu ZR, Jin YW, et al. Minimally invasive surgery for hilar cholangiocarcinoma: state of art and future perspectives. *ANZ J Surg* 2019;89:476–80.
12. Xu Y, Wang H, Ji W, et al. Robotic radical resection for hilar cholangiocarcinoma: perioperative and long-term outcomes of an initial series. *Surg Endosc* 2016;30:3060–70.
13. Liu QD, Chen JZ, Xu XY, et al. Incidence of port-site metastasis after undergoing robotic surgery for biliary malignancies. *World J Gastroenterol* 2012;18:5695–5701.
14. Gumbs AA, Jarufe N, Gayet B. Minimally invasive approaches to extrapancreatic cholangiocarcinoma. *Surg Endosc* 2013;27:406–14.
15. Li J, Tan X, Zhang X, et al. Robotic radical surgery for hilar cholangiocarcinoma: A single-centre case series. *Int J Med Robot* 2020;10:e2076. https://doi.org/10.1002/rcs.2076
16. Machado MA, Surjan RC, Basseres T, Makdissi F. Robotic repeat right hepatectomy for recurrent colorectal liver metastasis. *Ann Surg Oncol*. 2019;26:292–95.
17. Machado MA, Surjan RC, Ardengh AO, Makdissi F. Robotic left hepatectomy and Roux-en-Y hepaticojejunostomy after bile duct injury. *Ann Surg Oncol*. 2019;26:2981–84.
18. Machado MAC, Surjan RC, Makdissi F. Robotic ALPPS. *Ann Surg Oncol*. 2020;27:1174–79.