

Robotic Repeat Right Hepatectomy for Recurrent Colorectal Liver Metastasis

Marcel Autran Machado, MD, FACS^{1,2}, Rodrigo C. Surjan, MD^{1,2}, Tiago Basseres, MD², and Fabio Makdissi, MD^{2,3}

¹Department of Surgery, University of São Paulo, São Paulo, Brazil; ²Nove de Julho Hospital, São Paulo, Brazil;

³Department of Gastroenterology, University of São Paulo, São Paulo, Brazil

ABSTRACT

Background. Repeat hepatectomy often is required for primary and metastatic tumors. The purpose of this video was to present a robotic repeat hepatectomy for recurrent colorectal metastasis after multiple previous open surgeries.

Patient. A 64-year-old man underwent open left colectomy complicated by anastomotic leak. He was reoperated for colostomy, which was reverted. One year later, he underwent open metastasectomy. Recently, he presented a recurrence in the right liver, and a robotic right hepatectomy was indicated.

Technique. This approach used five trocars. The operation began with adhesiolysis. The next step was to dissect and divide the right hepatic artery and the right portal vein. A retrohepatic tunnel is created on the right side of the inferior vena cava for a modified liver hanging maneuver. The liver was pulled upwards and liver transection resumed towards the right hepatic vein. The liver was divided with bipolar forceps under continuous saline irrigation. The right hepatic duct was found inside the liver and was divided. Finally, the right hepatic vein was divided inside the liver parenchyma using a vascular stapler, and robotic right hepatectomy was completed.

Results. The operative time for docking was 10 min; adhesiolysis took 90 min while robotic right hepatectomy was completed in 240 min. The Pringle maneuver was not used. Estimated blood loss was 150 mL with no need for transfusion. Recovery was uneventful, and the patient was discharged on the fifth postoperative day.

Conclusions. Robotic repeat hepatectomy is feasible and safe in experienced hands and may have some advantages over laparoscopic and open repeat liver resections.

Repeat hepatectomy often is required for primary and metastatic tumors. However, this procedure may be technically demanding, so laparoscopic repeat hepatectomy has been used in few patients.^{1–4} Postoperative adhesions may increase operative time, complications, and conversion, especially in patients with previous open surgery. Multi-center studies have shown that laparoscopic repeat hepatic resections can be performed safely, especially in patients with previous laparoscopic resections.¹ The purpose of this video was to present a robotic repeat hepatectomy in a patient with recurrent colorectal metastasis and multiple previous open surgeries, including nonanatomical resection of S8.

METHODS

A 64-year-old man underwent an open left colectomy 4 years ago (2014) for colon cancer. Postoperative period was complicated by anastomotic leak, and he was reoperated for colostomy diversion. Colostomy was reverted 3 months later. At the same time, the incisional hernia was repaired. In 2015, a single, large metastasis in the right liver was diagnosed. He underwent open metastasectomy in S7/S8 that came with positive margins. The patient then received adjuvant chemotherapy with 12 cycles of Folfox.

Electronic supplementary material The online version of this article (<https://doi.org/10.1245/s10434-018-6996-2>) contains supplementary material, which is available to authorized users.

© Society of Surgical Oncology 2018

First Received: 4 July 2018

M. A. Machado, MD, FACS
e-mail: dr@drmarcel.com.br

Published online: 09 November 2018

However, in January 2018, a recurrence (3 tumors) in the right liver was seen. He then received 3 cycles of Folfiri and was referred to our service for treatment. Parenchymal-sparing hepatectomy was initially recommended, but further analysis showed that the larger metastasis was in close contact with the right pedicle. Therefore, a multidisciplinary team decided for a right hepatectomy. Preoperative liver volumetry estimated future liver remnant at 34%. The robotic approach was chosen. This study was approved by the review board of the Department of Surgery from our institution.

Surgical Technique

Patient Positioning and Port Placement The patient was placed in a supine position and 30° reverse Trendelenburg position. This technique used 5 trocars (Fig. 1). Pneumoperitoneum was created with an open technique in the future position of the camera (R0 in Fig. 1) as first trocar due to the presence of multiple incisions. Pneumoperitoneum was established at 14 mmHg. The surgeon is seated at the robotic console, and the assistant surgeon stands between the patient's legs. The assistant surgeon performs retraction, suction, clipping, stapling, and change of robotic instruments. The robotic system is placed at the patient's head for docking.

Adhesiolysis After pneumoperitoneum creation, multiples adhesions were found. Before docking, some adhesions were divided with laparoscopic instruments to allow insertion of remaining trocars. Once the abdominal

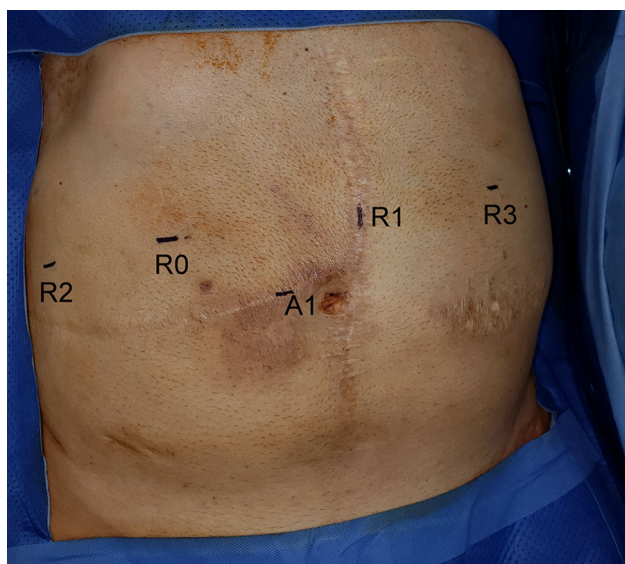


FIG. 1 Port placement for robotic right hepatectomy. R0 camera port, R1 first robot arm port, R2 second robot arm port, R3 third robot arm port, A1 assistant port

was cleared, the robotic arms were docked for the robotic phase.

The operation begins with meticulous division of adhesions. Care is taken not to damage any hollow organs. The small bowel was carefully retracted. With the use of robotic scissors and blunt dissection, most adhesions in front of the hepatic hilum are divided. The liver was stuck in the abdominal wall, and these adhesions were not divided at this time, because it was useful as a “natural” liver retraction.

Hilar Dissection Once the hepatic hilum is clearly visible, it is encircled with the Cadiere forceps, and an umbilical tape is passed. The Pringle maneuver is prepared for use in case of necessity. The gallbladder was removed previously, so the first step is to dissect the right hepatic artery using monopolar shears and bipolar Maryland forceps. The right hepatic artery had early division, and the right anterior and posterior arteries were divided separately between ligatures and hemolocks. The right portal vein is dissected and encircled with a vessel loop. Temporary clamping of the right portal vein results in ischemic delineation of the right liver. The right portal vein is then ligated and divided between hemolocks, and the proximal stump is immediately sutured with 4-0 polypropylene stitches. Because the biliary confluence was not low in this patient, it was left to be divided during parenchymal transection.

Liver Mobilization and Hanging Maneuver The next step is to complete the liver mobilization of the liver with division of adhesions that were kept for liver retraction. After completion of adhesiolysis, a retrohepatic tunnel is created on the right side of the inferior vena cava. An umbilical tape is pulled through this tunnel for a modified liver hanging maneuver. The tape is secured with the third robotic arm and liver is kept suspended.

Parenchymal Transection The future line of transection is marked with cautery, along the ischemic line. The liver is divided with the use of bipolar forceps under continuous saline irrigation. This technique produces a slow cooking of the liver tissue, and once it turns yellow, it can be divided with scissors. The transection progresses from the outer layer to the core of the liver parenchyma, in which there is higher vascularity, which also can be controlled exclusively by bipolar forceps. Venous branches from segments 5 and 8 were identified and also were controlled with bipolar cooking technique, but it took a longer time. The unique structure that required the use of ligature was the right hepatic duct, which was found inside the liver substance and was divided between the ligature and hemolocks. After division of the right hepatic duct, the

right paracaval caudate lobe was divided, and the umbilical tape was repositioned. The liver was then pulled upwards, and liver transection resumed towards the right hepatic vein. Finally, the right hepatic vein was divided inside the liver parenchyma using a vascular stapler. The specimen was then placed in a plastic retrieval bag and removed from the cavity. The liver surface was checked for bleeding and bile leak, and the abdominal cavity was drained with closed suction drain.

RESULTS

The operative time for docking was 10 min, adhesiolysis took 90 min, and robotic right hepatectomy was completed in 240 min. The Pringle maneuver was not used during the operation. Estimated blood loss was 150 mL with no need for intraoperative or postoperative transfusion. Recovery was uneventful, and the patient was discharged on the fifth postoperative day. The drain was removed on the seventh postoperative day. Pathology confirmed colorectal metastases with partial response (tumor regression grade 3, according Rubbia-Brandt classification).⁵ Surgical margins were free.

DISCUSSION

Abdominal open surgery usually results in postoperative adhesions that may increase the operative time of subsequent surgeries, due to the need for adhesiolysis. There also is increased risk of bowel injury, complications, and conversion to laparotomy in those patients.³ Modern oncological management of colorectal liver metastases frequently faces resectable recurrent metastatic disease. In this setting, repeat liver resection is indicated and positively impact survival.⁶

Open repeat hepatectomy is the standard of care, but there is an increasing number of laparoscopic liver resections being performed worldwide.⁷ Therefore, a patient previously submitted to laparoscopic surgery in need for a repeat liver resection is now common. In this situation, a repeat laparoscopy liver resection seems attractive. The first study to report the advantages of minimally invasive approach was published by Belli et al. and focused on recurrent hepatocellular carcinoma in cirrhotic patients.⁸ Furthermore, larger studies have shown that laparoscopic repeat hepatic resections can be performed safely, especially in patients with previous laparoscopic resections.¹⁻⁴ However, the indication criteria for the use of minimally invasive approach for repeat hepatectomy are not clear and probably are used only in selected cases.

In our service, we no longer avoid the use of laparoscopic approach in patients who have undergone previous open liver resection. The decision to perform a laparoscopic liver resection is the same regardless the presence of previous surgery in the upper abdomen.⁹ In the present case, after previous experience with both laparoscopic and robotic liver resection, we decided to use the robotic approach despite the likelihood to encounter severe adhesions. In fact, after removal of adhesions that prevented the insertion of trocars, the adhesiolysis was highly facilitated by the robotic approach and the use of the wristed instruments. This could reduce the risk of bowel injury and other complications. Liver resection can be performed after adhesiolysis and mobilization of the involved liver. However, hard and fibrotic adhesions can impede the visualization and dissection of the hepatic hilum that may be necessary to perform liver resections. The liver capsule may bleed during mobilization and division of adhesions, increasing blood loss and blurring the operative field.

We have been using the laparoscopic approach for repeat hepatectomy since 2013 with good results and low conversion rate (data not published). The use of a robotic system can improve certain steps of minimally invasive repeat liver resection.¹⁰ Magnified three-dimension vision allows for better definition of the surgical field that is modified by previous operations, thus improving recognition of hepatic hilum structures that permits selective inflow control.^{10,11} In a limited workspace, usually found in repeat liver resection, the use of wristed instruments allows precise dissection and suturing whenever necessary.

A recent systematic review and meta-analysis comparing robotic versus open live resection have shown that robotic approach resulted in a shorter hospital stay and less postoperative complications but longer operative time.¹¹

A matched comparison between robotic and laparoscopic hepatic resection showed no significant differences in operative outcomes.¹² However, a greater proportion of more complex major hepatectomies to be completed using robotic approach was observed.¹² Indeed, the presented case was unusually complex and was technically demanding. Thus, the robotic approach certainly facilitated the completion of the procedure in a totally minimally invasive approach. To the best of our knowledge, there is no description of a robotic repeat liver resection in the English literature.

CONCLUSIONS

Robotic repeat hepatectomy is feasible and safe in experienced hands and may have some advantages over laparoscopic and open repeat liver resections. This video may help oncological surgeons to perform this complex procedure.

REFERENCES

1. Shafer Z, Kazaryan AM, Marvin MR, et al. Is laparoscopic repeat hepatectomy feasible? A tri-institutional analysis. *J Am Coll Surg*. 2011;212:171–9.
2. Shelat VG, Serin K, Samim M, et al. Outcomes of repeat laparoscopic liver resection compared to the primary resection. *World J Surg*. 2014;38:3175–80.
3. Isetani M, Morise Z, Kawabe N, et al. Pure laparoscopic hepatectomy as repeat surgery and repeat hepatectomy. *World J Gastroenterol*. 2015;21:961–8.
4. Noda T, Eguchi H, Wada H, et al. Short-term surgical outcomes of minimally invasive repeat hepatectomy for recurrent liver cancer. *Surg Endosc*. 2018;32:46–52.
5. Rubbia-Brandt L, Giostra E, Brezault C, et al. Importance of histological tumor response assessment in predicting the outcome in patients with colorectal liver metastases treated with neo-adjuvant chemotherapy followed by liver surgery. *Ann Oncol*. 2007;18:299–304.
6. Butte JM, Gönen M, Allen PJ, et al. Recurrence after partial hepatectomy for metastatic colorectal cancer: potentially curative role of salvage repeat resection. *Ann Surg Oncol*. 2015;22:2761–71.
7. Ciria R, Cherqui D, Geller DA et al. Comparative short-term benefits of laparoscopic liver resection: 9000 cases and climbing. *Ann Surg*. 2016;263:761–77.
8. Belli G, Cioffi L, Fantini C, et al. Laparoscopic redo surgery for recurrent hepatocellular carcinoma in cirrhotic patients: feasibility, safety, and results. *Surg Endosc*. 2009;23:1807–11.
9. Machado MA, Surjan RC, Basseres T, et al. The laparoscopic Glissonian approach is safe and efficient when compared with standard laparoscopic liver resection: results of an observational study over 7 years. *Surgery*. 2016;160:643–51.
10. Wong DJ, Wong MJ, Choi GH et al. (2018) Systematic review and meta-analysis of robotic versus open hepatectomy. *ANZ J Surg*. <https://doi.org/10.1111/ans.14690>.
11. Giulianotti PC, Sbrana F, Coratti A, et al. Totally robotic right hepatectomy: surgical technique and outcomes. *Arch Surg*. 2011;146:844–50.
12. Tsung A, Geller DA, Sukato DC, et al. Robotic versus laparoscopic hepatectomy: a matched comparison. *Ann Surg*. 2014;259:549–555.