



ELSEVIER

Contents lists available at ScienceDirect

## Surgical Oncology

journal homepage: [www.elsevier.com/locate/suronc](http://www.elsevier.com/locate/suronc)

# Laparoscopic glissonean approach: Making complex something easy or making suitable the unsuitable?

Marcel A. Machado<sup>a,\*</sup>, Fábio Makdissi<sup>b</sup>, Rodrigo Surjan<sup>a</sup>

<sup>a</sup> Department of Surgery, University of São Paulo, Brazil

<sup>b</sup> Department of Gastroenterology, University of São Paulo, Brazil

## ARTICLE INFO

## Keywords:

Liver resection  
Laparoscopic  
Glissonean

## ABSTRACT

**Background:** The use of laparoscopic glissonean approach has many potential benefits such as shorter operative times, lower blood loss with low morbidity.

**Methods:** The aim with this study was to perform an evaluation of 12 years of our experience with laparoscopic glissonean approach in liver surgery, from a technical standpoint using a prospective database. Anatomical laparoscopic liver resections using hilar dissection and non-anatomical resections were excluded from this study.

**Results:** 327 patients (170 females and 157 males) with mean age of 56 years were included. 196 (60%) of procedures were major resections. 65% of procedures were performed in the last 5 years. 208 patients were operated on for secondary lesions. In 38 patients the liver was cirrhotic. Morbidity was 37.3% and 90-day mortality occurred in 2 patients (0.6%). Blood transfusion was necessary in 10.7% of patients. Median hospital stay was 4 days.

**Conclusions:** Laparoscopic glissonean approach is a safe and feasible technique. It may be preferred in some clinical situations as it is associated with shorter operative times, lower blood loss, and low morbidity. It is superior to standard laparoscopic hepatectomy when an anatomical resection, especially if a segment or section is to be removed. However, application of this technique requires accurate preoperative tumor localization, identification of potential anatomic pedicle variations, as well as surgeon expertise.

## 1. Introduction

The open glissonean approach to liver resection was established by Galperin et al. [1], Takasaki et al. [2], and Launois et al. [3]. To facilitate the selective clamping of glissonean pedicles, we published a simplification of this technique for both right and left livers in 2003 and 2004 [4,5]. The new approach, which uses small incisions at specific anatomical landmarks, allows for the highly selective control of pedicles without hilar or parenchymal dissection. This landmark-guided anatomic approach enables segmentectomies along ischemic demarcation lines in open liver surgery. Since 2007, we have also employed this same approach for laparoscopic liver resections; we have made a few modifications to accommodate the particularities of minimally invasive environments [6,7].

Here, we evaluate our 12 years of experience with laparoscopic glissonean approach in liver surgery from a technical standpoint using a prospective database.

## 2. Materials and methods

This observational study included patients at an urban referral center for liver tumors in São Paulo, Brazil. All patients undergoing liver resection at our institution are recorded in a database that is prospectively maintained by our HPB fellows and clinical study nurses and presented to a multidisciplinary tumor board. Laparoscopic liver resections are used based on location and extent of the disease. In this study, consecutive patients undergoing laparoscopic liver surgery using a glissonean approach between April 2007 and April 2019 were retrospectively studied. Anatomical laparoscopic liver resections using hilar dissection and non-anatomical resections were excluded from this study.

## 3. Surgical technique

Operation begins with an exploration of the abdominal cavity and an ultrasound liver examination. Patients are placed in the “French position” with the surgeon standing between the patient's legs. Four

\* Corresponding author. Rua Dona Adma Jafet 74 cj 102, 01308-050, São Paulo, Brazil.

E-mail address: [dr@drmarcel.com.br](mailto:dr@drmarcel.com.br) (M.A. Machado).

<https://doi.org/10.1016/j.suronc.2019.07.001>

Received 2 May 2019; Received in revised form 27 June 2019; Accepted 7 July 2019

0960-7404/ © 2019 Elsevier Ltd. All rights reserved.

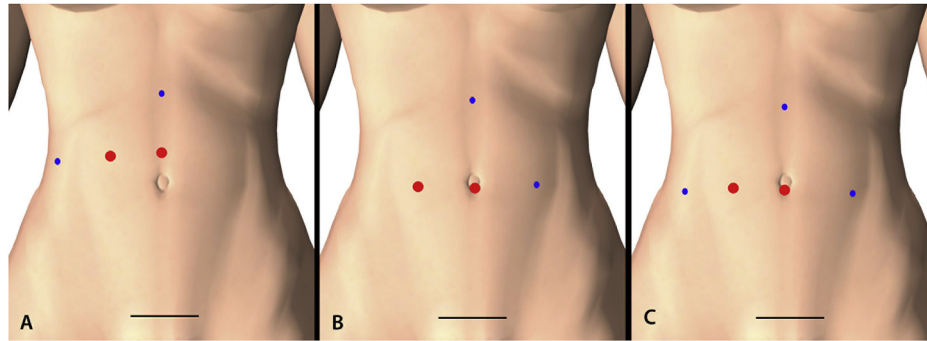


Fig. 1. Diagrams for trocar position. A. Right liver resection. B. Left liver resection. C. Bilateral liver resection.

trocars are normally used and may differ if a right, left liver or bilateral resection is proposed (Fig. 1).

### 3.1. Right liver glissonean approach

Three small liver incisions around the hilar plate are performed according to specific anatomical landmarks (Fig. 2A). Using two of these incisions, we can control the glissonean pedicle of the right liver (a to c), or, selectively, the anterior (a to b) or posterior (b to c) sections of the right hemiliver (Fig. 2B, C, 2D).

### 3.2. Left liver glissonean approach

Six small liver incisions around the left hilar plate are performed according to specific anatomical landmarks (Fig. 3A). Using two of these incisions, we can control the glissonean pedicle of the left liver (a to b), left lateral segments (a to d), segment 1 (a to f), segment 2 (a to e), segment 3 (d to e) and segment 4 (b to c). (Figs. 3 and 4).

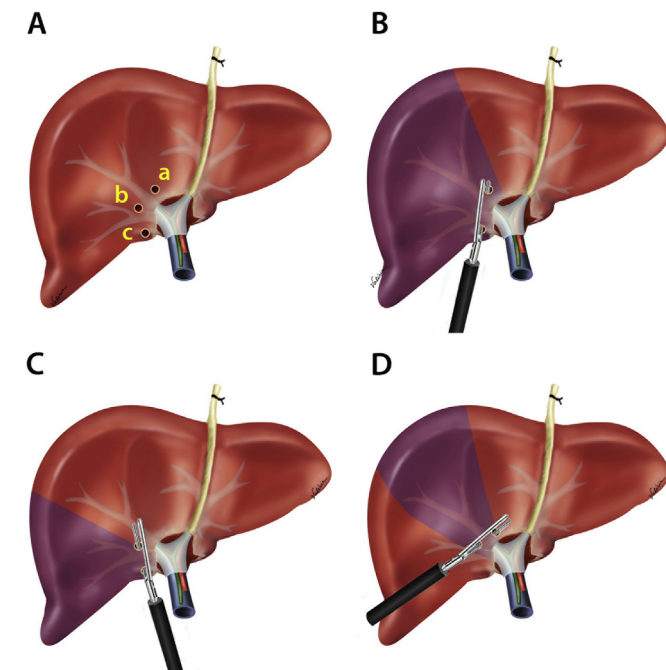


Fig. 2. Diagrams of anatomical landmarks for laparoscopic right glissonean approach. A. Incisions for the intrahepatic approach to the right Glissonian pedicles. Three small incisions are used: (a) incision directly above the hilum; (b) incision on the right edge of the gallbladder bed; (c) incision on segment 7 perpendicular to the hepatic hilum. B. Right hepatectomy. C. Right posterior sectionectomy (segments 6 and 7). D. Right anterior sectionectomy (segments 5 and 8).

### 3.3. Bilateral glissonean approach

Using a combination of right and left glissonean approach we can perform anatomical central hepatectomy (mesohepatectomy) and extended left and right liver resections (Fig. 5).

## 4. Results

Between 2007 and 2019, 327 laparoscopic liver resections using the glissonean approach were performed at our institution. Age, gender, tumor type (metastatic vs. Primary), and liver parenchymal quality (normal vs. cirrhotic) data are listed in Table 1. The type of laparoscopic liver resection is listed in Table 2. There was a marked increase in number and complexity of liver resections performed during the latter era (Table 2). The number of major liver resections was greater in the last period of the study (Table 2). This resulted in a significant increase in operative time and hospital stay (Table 3). However, the number of complications, blood transfusion, conversion, and 90-day mortality were not significantly different (Table 3).

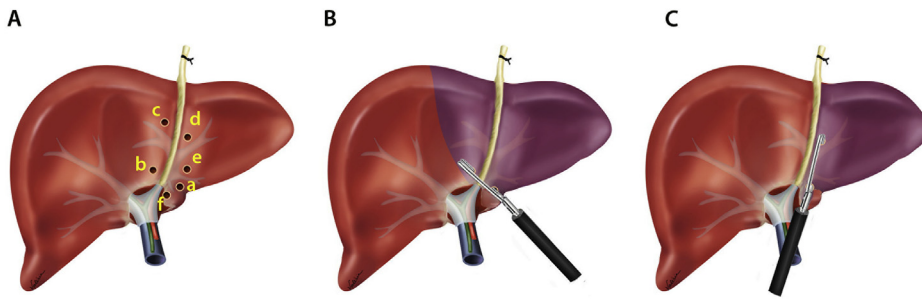
## 5. Discussion

In a previous study, we compared standard laparoscopic liver resections with those performed using an intrahepatic glissonean approach [8]. Fewer complications, shorter operative times, and less blood loss were observed in the glissonean approach comparing with standard laparoscopic liver resections [8]. Since then, this technique has been preferred over the standard approach in our Service. Indeed, 65% of our glissonean cases were performed from 2015 to 2019 (Table 1). Moreover, at least at our institution, this approach was characterized by safety and a high feasibility rate [8].

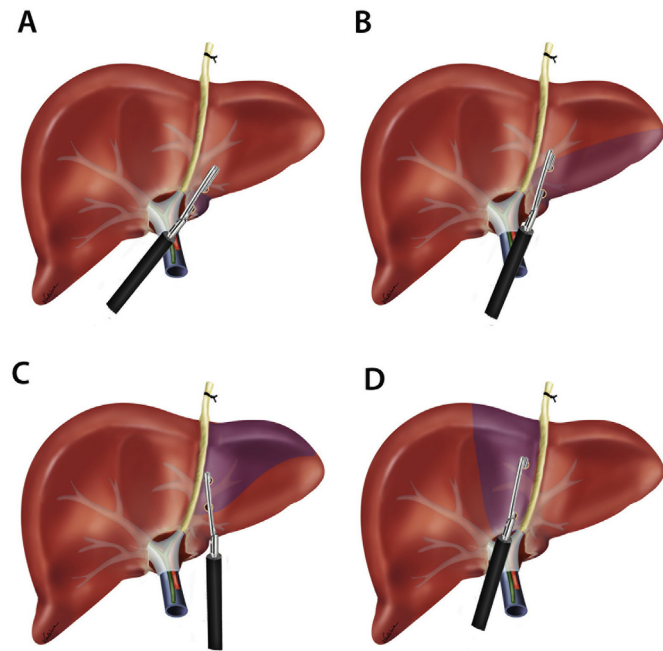
In a recent systematic review of the glissonean approach in both open and laparoscopic liver resections, Moris et al. [9] demonstrated that the glissonean approach is a safe and feasible method. This approach is associated with shorter operative times, less blood loss, and lower morbidity—it may be superior to standard laparoscopic liver resection techniques [9].

### 5.1. Right and left hemiliver resections

In the conventional approach of performing a laparoscopic right or left hepatectomy, structures in the hepatic hilum are dissected to expose the portal vein, hepatic artery and bile duct. Although this technique is a straightforward dissection in open surgery, it requires an extra skill in laparoscopic settings. Moreover, the time necessary to achieve complete dissection of these structures is significantly longer than that of the glissonean approach in which the pedicle can be encircled and controlled in a few minutes. A prospective, randomized study showed that the glissonean approach was faster than hilar dissection in open surgery [10]. In our laparoscopic group, this time was even longer in the dissected group. For a right hepatectomy, the median time to achieve



**Fig. 3.** Diagrams of anatomical landmarks for laparoscopic left glissonean approach. A. Incisions for the intrahepatic approach to the left Glissonian pedicles. (a) the caudal stump of the Arantius ligament; (b) the incision above the hilum; (c) the basis of the round ligament, right side; (d) the basis of the round ligament, left side; (e) midway between sites D and A; (f) caudate notch. B. Left hepatectomy C. Left lateral sectionectomy.



**Fig. 4.** Diagrams of anatomical laparoscopic monosegmentectomies. A. Segmentectomy 1. B. Segmentectomy 2. C. Segmentectomy 3. D. Segmentectomy 4.

control of the portal triad was 37 min vs 13 min for the intrahepatic glissonean approach ( $P < 0.01$ ). For a left hepatectomy, the time difference was also statistically significant (31 min vs 9 min;  $P < 0.05$ ). It is important to state that in some circumstances there is contraindication for using the glissonean approach (e.g., proximity of the tumor to the glissonean pedicle). Hilar cholangiocarcinoma is also a contraindication for this technique, but the laparoscopic approach is still rarely used [11]. In some patients, the pedicles from the anterior and posterior section are distinct and needed to be controlled separately. On the other hand, there are special circumstances in which the glissonean approach is preferred over the conventional approach. In

**Table 1**

Demographics of patients with laparoscopic glissonean approach.

Variable of interest	n = 327
Age, years, median (range)	56 (17–85)
Sex, male/female, n (%)	157/170 (48%/52%)
Type of operation	
Minor, n (%)	131 (40%)
Major, n (%)	196 (60%)
Era of operation	
2007–2010, n (%)	34 (10.4%)
2011–2014, n (%)	80 (24.6%)
2015–2019, n (%)	213 (65%)
Tumor type	
Primary <sup>a</sup> , n (%)	119 (36.4%)
Secondary, n (%)	208 (63.6%)
Liver parenchyma	
Normal, n (%)	289 (88.4%)
Cirrhosis, n (%)	38 (11.6%)

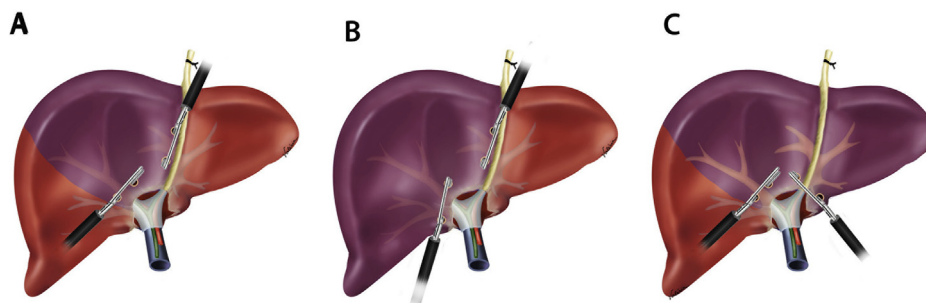
<sup>a</sup> Includes benign tumors and benign conditions such as intrahepatic lithiasis.

**Table 2**

Type of laparoscopic liver resection using glissonean approach according to the era of operation (2007–2019).

Procedure	2007–2010 (n = 34)	2011–2014 (n = 80)	2015–2019 (n = 213)
<b>Left Liver</b>			
S1	0	2	7
S2	0	1	4
S3	2	1	5
S4	1	4	16
S2–S3	12	28	15
Left Hemihepatectomy <sup>a</sup>	4 <sup>a</sup>	7 <sup>a</sup>	54 <sup>b</sup>
<b>Right Liver</b>			
S5–S8	1	2	6
S6–S7	3	6	15
Right Hemihepatectomy <sup>a</sup>	9 <sup>a</sup>	23 <sup>a</sup>	59 <sup>b</sup>
<b>Bilateral</b>			
Trisectionectomy <sup>a</sup>	1 <sup>a</sup>	4 <sup>a</sup>	21 <sup>b</sup>
Mesohepatectomy <sup>a</sup>	1 <sup>a</sup>	2 <sup>a</sup>	11 <sup>b</sup>

<sup>a</sup> Major liver resections - a vs b;  $P < 0.0001$ .



**Fig. 5.** Diagrams of anatomical laparoscopic bilateral anatomical resections. A. Mesohepatectomy (S4/S5/S8) B. Left trisectionectomy. C. Right trisectionectomy.

**Table 3**  
Outcome of laparoscopic liver resection using glissonean approach according to the era of operation (2007–2019).

Variable	2007–2010 (n = 34)	2011–2014 (n = 80)	2015–2019 (n = 213)	P value
Operative time, minutes, mean	122	146	166	<b>0.0269<sup>a</sup></b>
Patients transfused, n (%)	5 (14.7)	10 (12.5)	20 (9.4)	0.2935 <sup>a</sup>
Conversion, n (%)	0	2 (2.5)	6 (2.8)	0.5534 <sup>a</sup>
Overall complications	15 (44)	35 (43.7)	72 (33.8)	0.0731 <sup>a</sup>
Hospital stay, days, median	2	3	5	<b>0.0228<sup>a</sup></b>
90-day mortality, n (%)	0	1 (1.2)	1 (0.4%)	0.6522 <sup>a</sup>

<sup>a</sup> Era 2007–2014 combined vs Era 2015–2019.

patients with previous dissection of the hepatic hilum, individual dissection of the portal triad may be difficult or even hazardous [12]. Good examples of this situation include the second stage of the ALPPS procedure, a bile duct complex injury with vascular damage requiring liver resection and re-hepatectomies. Therefore, a liver surgeon who wishes to perform laparoscopic hepatectomies should be able to perform both techniques. We have published two multimedia articles with a technical description of right [13] and left [14] laparoscopic hepatectomies using the glissonean approach.

### 5.2. Resection of the right anterior (S5/S8) and posterior sections (S6/S7)

The conventional approach employs dissection of the hepatic hilum structures. Although it is theoretically possible to reach the second ramification of the portal vein and hepatic artery, this approach is rarely used given its inherent difficulty. The use of anatomic approximation or laparoscopic ultrasonography with extrapolation of resection lines may result in ischemic remnants owing to incorrect mapping [8]. Most authors use an intrahepatic glissonean approach if the right anterior or posterior section is to be performed [15,16]. In our experience, the feasibility of right posterior sectionectomy is high, but the glissonean pedicle from the anterior section is variable and sometimes an extended dissection of the hilar plate is warranted to correct the positioning of the vascular clamp. In our series, nine cases of right anterior sectionectomy were performed. In two cases, correct ischemic delineation was not obtained after the first attempt and additional dissection was necessary. Details of the technique for the laparoscopic approach for the right anterior and posterior section can be observed in a multimedia article from our group [17].

### 5.3. Resection of the left lateral section (segments 2 and 3)

This technique is the easiest laparoscopic resection to perform, and several methods can be used with similar results. The intrahepatic glissonean approach is an elegant one for this resection but not necessary in most cases. A simple opening of the liver parenchyma anterior to the pedicles from segments 2 and 3 is sufficient to reach these pedicles and enable the precise insertion of a stapler. However, there are some situations in which the glissonean approach may be preferable. Large tumors with complete involvement of the left lateral section may be better resected using the glissonean technique because opening the liver tissue may compromise the oncological character of the surgery and the limit of this section may not be evident. In this instance, a quick control of the pedicle will result in ischemic delineation of the segments and the margins of both liver and tumor will be clear [17]. Furthermore, the correct margin of segments 2 and 3 may be far away from the falciform ligament in cirrhotic patients. Therefore, control of the pedicles prior to liver transection may spare some liver parenchyma that is important in these patients.

### 5.4. Monosegmentectomies (segments 1, 2, 3 and 4)

This type of liver-sparing resection needs dissection and control of the glissonean pedicle to be performed. This highly anatomic resection

can be facilitated by this technique [17,18]. The feasibility is extremely high, and the ischemic delineation helps the liver transection. However, the segment 1 resection described herein does not include the pedicle from the paracaval portion that can be reached from the right side.

As in most anatomical resections, an intraoperative ultrasound is mandatory to preserve the hepatic vein branch from the remaining segments. In colorectal metastasis settings, the maximum preservation of the parenchyma is important. Most patients recur, but if a liver-sparing technique is used the patient has a higher probability of being able to undergo a re-hepatectomy. Another important use is during the ALPPS procedure, when the future liver remnant is too small [12]. The use of segmentectomy instead of sectionectomy or hemiliver resection may allow a patient to become resectable.

### 5.5. Monosegmentectomies (segments 5, 6, 7 and 8)

Only few monosegmentectomies can be accurately performed using the straightforward glissonean technique. Anatomical isolated resection of right segments 5, 6, 7 and 8 are possible but to achieve complete delineation using intrahepatic glissonean technique, further dissection into the liver parenchyma are necessary. Therefore, this type of liver resection was not included in this series.

### 5.6. Anatomical bilateral resections (mesohepatectomy and trisectionectomies)

Laparoscopic extended and central liver resections are complex procedures and rarely performed [19,20]. This type of resection accounts for 12.2% of our procedures (Table 2). According to the last consensus conference of laparoscopic liver surgery, these types of surgery have a steep learning curve and are the most complex and may be performed only by surgeons with a high level of technical skill [21,22]. The use of the glissonean approach is important to achieve delineation of the central liver segments in mesohepatectomy and in right and left trisectionectomies. These approaches can be seen in multimedia articles from our group [19,23].

## 6. Conclusions

The glissonean technique in laparoscopy can be used to perform not only major hepatic resections but also anatomically tailored monosegmentectomies or bisegmentectomies, which enable parenchymal-sparing resections. Better delineation of segmental borders may avoid partially ischemic and nonfunctional remnants, which may be a source of infection and necrosis.

A laparoscopic glissonean approach is a safe and feasible technique. It may be preferred in some clinical situations because it is associated with shorter operative times, less blood loss, and lower morbidity than standard technique. It is superior to a standard laparoscopic hepatectomy when an anatomical resection, especially a segment or section, is to be removed. However, it is important to stress that appropriate application of this technique requires accurate preoperative tumor localization, identification of potential anatomic pedicle variations, as well as expertise on the part of the surgeon to be successful.



### Conflict-of-interest statement

The authors declare no conflicts of interest.

### Appendix A. Supplementary data

Supplementary data to this article can be found online at <https://doi.org/10.1016/j.suronc.2019.07.001>.

### References

- [1] E.I. Galperin, S.R. Karagiulian, A new simplified method of selective exposure of hepatic pedicles for controlled hepatectomies, *HPB Surg.* 1 (1989) 119–130.
- [2] K. Takasaki, S. Kobayashi, S. Tanaka, et al., Highly anatomically systematized hepatic resection with Glissonian sheath code transection at the hepatic hilus, *Int. Surg.* 75 (1990) 73–77.
- [3] B. Launois, G.G. Jamieson, The posterior intrahepatic approach for hepatectomy or removal of segments of the liver, *Surg. Gynecol. Obstet.* 174 (1992) 155–158.
- [4] M.A. Machado, P. Herman, M.C. Machado, A standardized technique for right segmental liver resections, *Arch. Surg.* 138 (2003) 918–920.
- [5] M.A. Machado, P. Herman, M.C. Machado, Anatomical resection of left liver segments, *Arch. Surg.* 139 (2004) 1346–1349.
- [6] M.A. Machado, F.F. Makdissi, F.H. Galvão, et al., Intrahepatic Glissonian approach for laparoscopic right segmental liver resections, *Am. J. Surg.* 196 (2008) e38–e42.
- [7] M.A. Machado, F.F. Makdissi, R.C. Surjan, et al., Laparoscopic resection of left liver segments using the intrahepatic Glissonian approach, *Surg. Endosc.* 23 (2009) 2615–2619.
- [8] M.A. Machado, R.C. Surjan, T. Basseres, E. Schadde, F.P. Costa, F.F. Makdissi, The laparoscopic Glissonian approach is safe and efficient when compared with standard laparoscopic liver resection: results of an observational study over 7 years, *Surgery* 160 (3) (2016 Sep) 643–651.
- [9] D. Moris, A.A. Rahnemai-Azar, D.I. Tsilimigras, et al., Updates and critical insights on glissonian approach in liver surgery, *J. Gastrointest. Surg.* 22 (2018) 154–163.
- [10] J. Figueras, S. Lopez-Ben, L. Lladó, et al., Hilar dissection versus the “glissonian” approach and stapling of the pedicle for major hepatectomies: a prospective, randomized trial, *Ann. Surg.* 238 (2003) 111–119.
- [11] M.A. Machado, F.F. Makdissi, R.C. Surjan, M. Mochizuki, Laparoscopic resection of hilar cholangiocarcinoma, *J. Laparoendosc. Adv. Surg. Tech.* 22 (2012) 954–956.
- [12] M.A. Machado, R.C. Surjan, T. Bassères, F.F. Makdissi, Totally laparoscopic ALPPS for multiple and bilobar colorectal metastases (with video), *J. Vis. Surg.* 154 (2017) 131–132.
- [13] M.A. Machado, R.C. Surjan, F.F. Makdissi, Intrahepatic Glissonian approach for pure laparoscopic right hemihepatectomy, *Surg. Endosc.* 25 (2011) 3930–3933.
- [14] M.A. Machado, F.F. Makdissi, P. Herman, R.C. Surjan, Intrahepatic Glissonian approach for pure laparoscopic left hemihepatectomy, *J. Laparoendosc. Adv. Surg. Tech.* 20 (2) (2010 Mar) 141–142.
- [15] C.W. Cho, J. Rhu, C.H.D. Kwon, et al., Short-term outcomes of totally laparoscopic central hepatectomy and right anterior sectionectomy for centrally located tumors: a case-matched study with propensity score matching, *World J. Surg.* 41 (2017) 2838–2846.
- [16] K.C. Cheng, Y.P. Yeung, K.M. Ho, F.K. Chan, Laparoscopic right posterior sectionectomy for malignant lesions: an anatomic approach, *J. Laparoendosc. Adv. Surg. Tech.* 25 (2015) 646–650.
- [17] M.A.C. Machado, R. Surjan, T. Basseres, F. Makdissi, Laparoscopic parenchymal-sparing liver resections using the intrahepatic glissonian approach, *Ann. Surg. Oncol.* 24 (2017) 2353–2354.
- [18] M.A. Machado, R. Surjan, T. Bassères, F. Makdissi, Laparoscopic resection of caudate lobe. Technical strategies for a difficult liver segment. Video article, *Surg Oncol* 27 (2018) 674–675.
- [19] M.A. Machado, A.N. Kalil, Glissonian approach for laparoscopic mesohepatectomy, *Surg. Endosc.* 25 (6) (2011 Jun) 2020–2022.
- [20] M.A. Machado, R. Surjan, T. Bassères, F. Makdissi, Extended laparoscopic liver resection: initial experience and review of the literature, *Ann Laparosc Endosc Surg* 2 (2017) 32–37.
- [21] G. Wakabayashi, D. Cherqui, D.A. Geller, et al., Recommendations for laparoscopic liver resection: a report from the second international consensus conference held in Morioka, *Ann. Surg.* 261 (2015) 619–629.
- [22] J.Y. Cho, H.S. Han, G. Wakabayashi, et al., Practical guidelines for performing laparoscopic liver resection based on the second international laparoscopic liver consensus conference, *Surg Oncol* 27 (2018) A5–A9.
- [23] M.A. Machado, F.F. Makdissi, R.C. Surjan, et al., Intrahepatic Glissonian approach for laparoscopic right trisectionectomy, *J. Laparoendosc. Adv. Surg. Tech.* 19 (2009) 777–778.