

INNOVATION IN SURGERY

A simple technique for hemostasis control after enucleation of deep located liver tumors or after liver trauma

Marcel A. Machado*, Rodrigo C. Surjan, Tiago Basseres, and Fábio F. Makdissi

Department of Surgery, Sirio Libanes Hospital, São Paulo, Brazil

*Correspondence address. Rua Dona Adma Jafet 74 cj 102, 01308-050 São Paulo, Brazil. Tel: +55-11-3256-4098; Fax: +55-11-3259-8231; E-mail: dr@drmarcel.com.br

Abstract

Modern liver techniques allowed the development of segment-based anatomical liver resections. Nevertheless, there is still a place for nonanatomical liver resections. However, in some cases, there is a need for enucleation of deep located liver tumors. The main problem with enucleation of a liver tumor deeply located in the middle of the liver is the control of bleeding resulting from the rupture of small or medium vessels. The authors describe a simple way to control the bleeding without the use of any special instrument or material. This technique can also be used to control bleeding from penetrating liver injury.

INTRODUCTION

Modern liver techniques allowed the development of segment-based anatomical liver resections [1–3]. Nevertheless, there is still a place for nonanatomical liver resections [4]. Enucleation of small lesions located near the hepatic surface is achieved with low morbidity and mortality and is a current practice among surgeons. However, in some cases, there is a need for enucleation of deep located liver tumors. Another option is to use radioablation of these tumors, but this option is not always available and may result in high recurrence in inexperienced hands. The main problem with enucleation of a liver tumor deeply located in the middle of the liver is the control of bleeding resulting from the rupture of small or medium vessels. It is impossible to reach these vessels without enlarging the opening. The authors describe a simple way to control the bleeding without the use of any special instrument or material. This technique can also be used to control bleeding from stellate liver lesions after blunt or penetrating liver injury.

OPERATIVE TECHNIQUE

After identification of the lesion by inspection and intraoperative ultrasonography, Glisson's capsule is marked with electrocautery 2 cm away from the tumor margin. The marked area is checked by ultrasonography to ascertain surgical margin right before liver transection. Hemihepatic ischemia or Pringle maneuver can be applied, according to location of the tumor. Parenchymal transection is performed with bipolar forceps or the crush technique. After removal of the tumor, a large and deep defect is produced, often with minor or major bleeding. The technique consists of filling the defect with any absorbable hemostatic tissue available, such as Surgicel (Ethicon, Cincinnati, OH, USA), and wait until this hemostatic tissue is imbued with blood. The cautery is put at maximum power in coagulate mode and the blood is cooked until a crust is formed (Fig. 1).

DISCUSSION

Although anatomical resection, which allows a better clearance between tumor deposits and the cut section of the

Received: November 9, 2015. Accepted: January 4, 2016

Published by Oxford University Press and JSCR Publishing Ltd. All rights reserved. © The Author 2016.

This is an Open Access article distributed under the terms of the Creative Commons Attribution Non-Commercial License (<http://creativecommons.org/licenses/by-nc/4.0/>), which permits non-commercial re-use, distribution, and reproduction in any medium, provided the original work is properly cited. For commercial re-use, please contact journals.permissions@oup.com

liver, is recommended as a standard procedure for liver tumors, nonanatomical resection is quite feasible for small tumors with little risk of microscopic local invasion [5–7]. Indeed, liver resection of peripheric small lesions is feasible and can be done with minimum morbidity and mortality rates. Enucleation is also used to remove small liver tumors from the future liver remnant after major liver resections. Enucleation of deep located liver tumors may result in rupture of small venous or portal branches that are not always easy to control. Usually, temporary compression may reduce or even stop the bleeding. However, bleeding may resume and cause postoperative bleeding. A definitive hemostasis is advised.

Another common situation that may be a good indication for the present technique is penetrating abdominal trauma with liver injury. Usually, multiple stellate liver injuries are not easy to control and liver packing may be necessary for damage control. Even radiofrequency has been suggested for bleeding control after penetrating liver trauma [8]. This technique may

help dealing with these injuries without the use of any special equipment.

The present technique is feasible in every liver segment. It did not require any fancy device or instrument, and it is an important adjunct for the treatment of multiple liver tumors. We have been used this technique for hemostasis control after nonanatomical liver resections since 2012, with excellent results. This technique is useful in combination with anatomical liver resections, such as right and left hemihepatectomies, or two-stage liver resections. This technique can also be used during laparoscopic liver resections.

The described technique is quite simple, and facilitates bleeding control after liver enucleations. It is also useful to control the bleeding from penetrating liver injury and therefore can be an important tool for the general surgeon.

CONFLICT OF INTEREST STATEMENT

None declared.

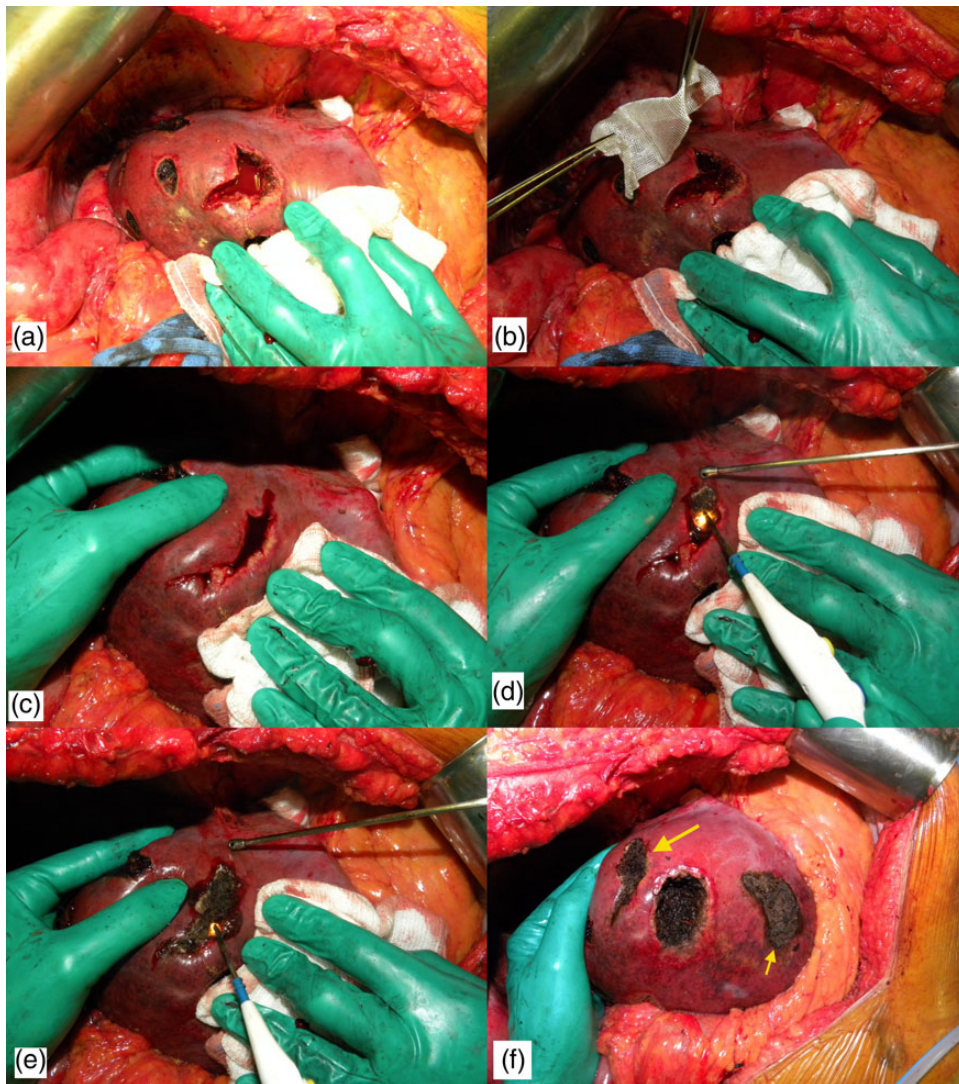


Figure 1: Technique of bleeding control. (a) Intraoperative photograph after enucleating a deep located metastasis. Note that there is a profuse bleeding. (b) Hemostatic tissue is inserted inside the defect. (c) Hemostatic tissue is imbibed with blood and liver borders are brought together with manual compression. (d) The cautery is put at maximum power in coagulate mode and the blood is cooked until a crust is formed. (e) The lateral compression is released and some residual bleeding is controlled with cautery. (f) Final view after the use of the technique (larger arrow). Note that another enucleated area was controlled with the same technique (smaller arrow).

REFERENCES

1. Billingsley KG, Jarnagin WR, Fong Y, Blumgart LH. Segment-oriented hepatic resection in the management of malignant neoplasms of the liver. *J Am Coll Surg* 1998;**187**:471–81.
2. Machado MA, Herman P, Machado MC. Standardized technique for segmental right liver resections. *Arch Surg* 2003;**138**:918–20.
3. Machado MA, Herman P, Machado MC. Anatomical resection of left liver segments. *Arch Surg* 2004;**139**:1346–9.
4. Yamamoto J, Saiura A, Koga R, et al. Surgical treatment for metastatic malignancies. Nonanatomical resection of liver metastasis: indications and outcomes. *Int J Clin Oncol* 2005;**10**:97–102.
5. DeMatteo RP, Palese C, Jarnagin WR, et al. Anatomic segmental hepatic resection is superior to wedge resection as an oncologic operation for colorectal liver metastases. *J Gastrointest Surg* 2000;**4**:178–84.
6. Sui CJ, Cao L, Li B, et al. Anatomical versus nonanatomical resection of colorectal liver metastases: a meta-analysis. *Int J Colorectal Dis* 2012;**27**:939–46.
7. Lalmahomed ZS, Ayez N, van der Pool AE, et al. Anatomical versus nonanatomical resection of colorectal liver metastases: is there a difference in surgical and oncological outcome? *World J Surg* 2011;**35**:656–61.
8. Recordare A, Bruno GT, Callegari P, et al. Bleeding control by radiofrequency in penetrating trauma of the liver. *G Chir* 2011;**32**:203–5.