

# A New Technique for Liver Retraction During Single-Port Laparoscopic Surgery

Rodrigo C.T. Surjan, MD, Fabio F. Makdissi, MD, and Marcel Autran C. Machado, MD

## Abstract

Establishing a clear operative viewing field and adequate working space are essential steps for safe laparoscopic surgery. This aim of this article is to report a new technique of liver retraction during upper gastrointestinal laparoscopic surgery. This technique is fast and simple and precludes the use of special devices. It avoids the use of a subxiphoid trocar exclusive for liver retraction. This technique was designed to be used in single-port laparoscopic surgery but can be used in standard laparoscopic surgery to reduce the number of trocars. The first step is to perform division of the left triangular ligament. The fibrous appendix is identified. A window in the falciform ligament is created. The fibrous appendix is sutured to the peritoneum in the right subcostal area. The left lobe of the liver passes through the window in the falciform ligament, avoiding liver congestion. Optimum exposure of the upper gastrointestinal area is achieved. This new technique is easy and can be performed in various types of laparoscopic gastrointestinal surgeries without the need for specific skills or devices. We believe that our liver retraction technique is useful in single-port laparoscopic surgery and allows an excellent exposure of the upper gastrointestinal tract.

## Introduction

ESTABLISHING A CLEAR operative viewing field and adequate working space are essential steps for safe laparoscopic surgery. In patients requiring surgery of the gastrointestinal tract, the lateral segment of the liver often interferes with the surgical field.<sup>1,2</sup> This may be of special importance in obese patients. Thus, many laparoscopic surgeons have devised techniques to retract the left lobe of the liver to completely expose the gastrohepatic ligament near the esophageal hiatus and the hepatoduodenal ligament during laparoscopic surgery.<sup>1-8</sup> The main method is the use of 5-mm or 10-mm laparoscopic liver retractors inserted through an additional trocar placed in the subxiphoid area. In the past decade, minimal access surgery is moving toward minimizing the surgical trauma by reducing the numbers and size of the trocars. Therefore, some authors have described the use of alternative techniques to retract the liver without the subxiphoid trocar.<sup>9-13</sup> More recently, the reduction of trocars reached the ultimate goal with the advent of single-port laparoscopic surgery.

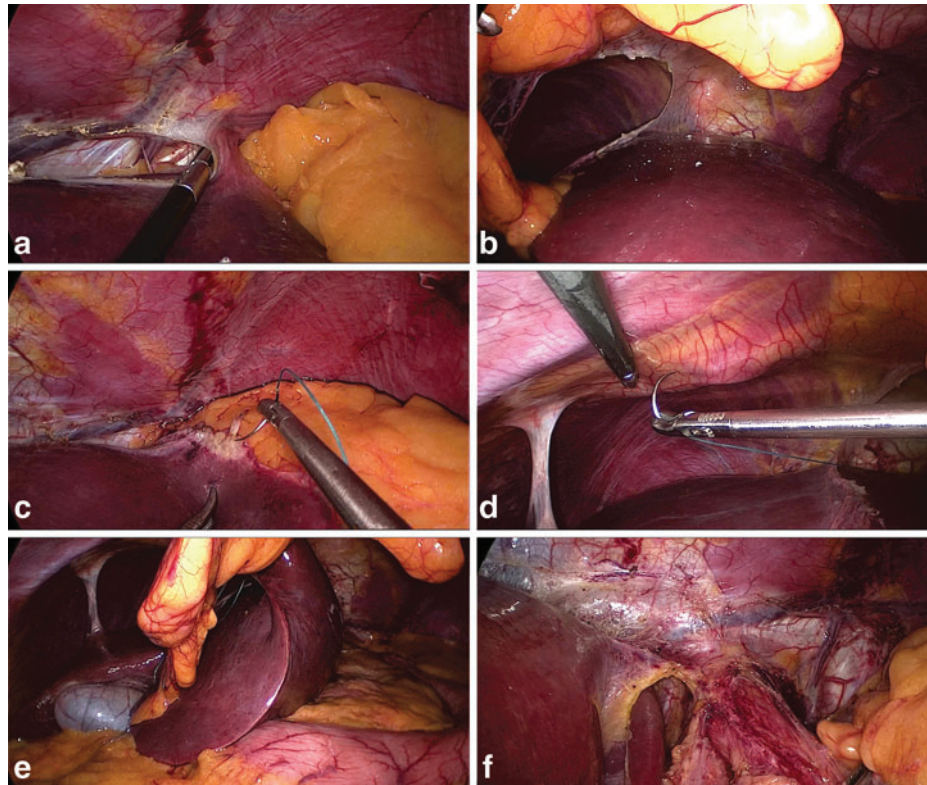
This aim of this article is to report a new technique of liver retraction during upper gastrointestinal laparoscopic surgery. This technique is fast and simple and precludes the use of special devices. It avoids the use of a subxiphoid trocar exclu-

sive for liver retraction. This technique was designed to be used in single-port laparoscopic surgery but can be used in standard laparoscopic surgery to reduce the number of trocars.

## Operative Technique

### *Single-port assembly*

The patient is placed in a supine and reverse Trendelenburg position with the surgeon between the patient's legs. The first assistant is on the right side of the patient, with the monitor placed on the patient's cranial side. With the patient under general anesthesia, a transumbilical 3-cm skin incision is performed. A single-incision advanced access platform with a gelatin cap, self-retaining sleeve, and wound protector (Gel-Point®; Applied Medical, Rancho Santa Margarita, CA) is introduced through this incision. Three 5–10-mm trocars are introduced through the single-port device. Because of the gel cap and sleeves, no special articulated instruments are necessary. CO<sub>2</sub> pneumoperitoneum is established at 12 mm Hg. A rigid 30° 10-mm laparoscope is introduced. This single-port platform is able to accommodate at the same time three or four instruments with no triangulation prejudice depending on the configuration needed. This configuration allows enough mobility and triangulation with a 30-mm skin and aponeurosis opening, which was applied in all cases.



**FIG. 1.** The new technique for liver retraction. (a) The left triangular ligament is divided with cautery. A fibrous appendix is seen. (b) A window is created in the falciform ligament. (c) The fibrous appendix is identified, and a 2-0 Mersilene suture is applied. (d) The fibrous appendix is sutured to the peritoneum in the right subcostal area. (e) The left lobe of the liver is pulled through the falciform ligament window. (f) Optimum exposure of the upper gastrointestinal area is obtained.

#### *Liver retraction*

The main objective of this new technique is to make the esophagogastric junction visible by folding the left lobe of the liver upon itself. The first step is to perform division of the left triangular ligament, leaving the fibrous appendix intact (Fig. 1a). A window in the falciform ligament is created without division of the round ligament (Fig. 1b). The fibrous appendix is divided far from the liver, and a 2-0 poly(ethylene terephthalate) (Mersilene™; Ethicon, Somerville, NJ) suture is applied in this fibrous tissue that is strong enough to support the left lobe of the liver (Fig. 1c). The fibrous appendix is sutured to the peritoneum in the right subcostal area (Fig. 1d). The left lobe of the liver passes through the opening in the falciform ligament, avoiding liver congestion (Fig. 1e). The upper gastrointestinal area is clearly visible, leading to an optimum exposure (Fig. 1f).

#### **Discussion**

Exposure of the operating field and comfortable working space are key elements on laparoscopic surgery. For upper gastrointestinal laparoscopic surgery such as Nissen fundoplication or gastric or bariatric surgery, the left lateral segment of the liver often interferes with the surgical field. Usually, an additional subxiphoid trocar is necessary exclusively to retract the liver, and the use of laparoscopic liver retractors may result in postoperative liver damage, as previously reported.<sup>14</sup> Therefore, in upper abdominal tract laparoscopic

surgery, a safe and efficient method of liver retraction is of paramount importance.

Retraction of the left lobe of the liver without inserting an additional trocar poses a major problem in single-port or even standard laparoscopic surgery.<sup>9-13</sup> The main objective of this new technique is to make the esophagogastric junction visible by folding the left lobe of the liver upon itself.<sup>11</sup> However, this maneuver alone may not be enough in thick or large livers or may cause liver congestion and subsequently a transient postoperative rise in aminotransferase levels. Usually, the falciform ligament acts as an obstacle to this maneuver. Therefore, we created an opening in the falciform ligament to facilitate this task. With this maneuver, even a large and thick liver can be fold upon itself, increasing the visibility of the operating field without liver congestion (Fig. 1e).

Several other techniques have been described to retract the left lateral segment of the liver during laparoscopic surgery. Sakaguchi et al.<sup>4</sup> reported a lifting technique using a Penrose drain and a J-shaped retractor during laparoscopic gastrectomy. Woo et al.<sup>8</sup> described a liver suspension using gauze suture. Some authors have described good results with the use of a flexible silicone disk to facilitate liver retraction.<sup>1,3,9</sup> However, these techniques may not always preclude the use of a liver retractor or subxiphoid trocar.<sup>1,3</sup> Moreover, the silicone disk is not available worldwide and maybe costly.

Retraction of the liver during single-port laparoscopic upper abdominal tract surgeries is even more challenging than conventional laparoscopy.<sup>10-13</sup> In patients with a

hypertrophic and steatotic left lateral lobe of the liver, retraction of the liver with thin retractors is more difficult and may carry a risk of liver injury. Our technique may reduce the risk of liver damage.

In conclusion, our technique is easy and safe compared with other retraction techniques. The procedure can be performed in various types of laparoscopic gastrointestinal surgeries without the need for specific skills or devices. We believe that our retraction technique is useful in single-port laparoscopic surgery of the upper gastrointestinal tract and allows an excellent exposure of the upper gastrointestinal tract.

#### Disclosure Statement

No competing financial interests exist.

#### References

1. Saeki H, Oki E, Kawano H, Ando K, Ida S, Kimura Y, Morita M, Kusumoto T, Ikeda T, Maehara Y. Newly developed liver-retraction method for laparoscopic gastric surgery using a silicone disc: The  $\phi$ -shaped technique. *J Am Coll Surg* 2013;216:e43–e46.
2. Harari AA, Hochman B, Bessler M. A new technique for intracorporeal liver retraction in laparoscopic surgery. *Surg Obes Relat Dis* 2013;9:143.
3. Shibao K, Higure A, Yamaguchi K. Disk suspension method: A novel and safe technique for the retraction of the liver during laparoscopic surgery (with video). *Surg Endosc* 2011;25:2733–2737.
4. Sakaguchi Y, Ikeda O, Toh Y, Aoki Y, Harimoto N, Taomoto J, Masuda T, Ohga T, Adachi E, Okamura T. New technique for the retraction of the liver in laparoscopic gastrectomy. *Surg Endosc* 2008;22:2532–2534.
5. Shinohara T, Kanaya S, Yoshimura F, Hiramatsu Y, Haruta S, Kawamura Y, Giacomuzzi S, Fujita T, Uyama I. A protective technique for retraction of the liver during laparoscopic gastrectomy for gastric adenocarcinoma: Using a Penrose drain. *J Gastrointest Surg* 2011;15:1043–1048.
6. Lee IS, Kim TH, Yook JH, Kim HS, Kim BS, Kim BS. A triangle method: Simple suture retraction for the left lobe of the liver during laparoscopic gastric surgery. *J Laparoendosc Adv Surg Tech A* 2012;22:989–991.
7. Zachariah SK, Tai CM, Chang PC, Se AO, Huang CK. The “T-suspension tape” for liver and gallbladder retraction in bariatric surgery: Feasibility, technique, and initial experience. *J Laparoendosc Adv Surg Tech A* 2013;23:311–315.
8. Woo Y, Hyung WJ, Kim HI, Obama K, Son T, Noh SH. Minimizing hepatic trauma with a novel liver retraction method: A simple liver suspension using gauze suture. *Surg Endosc* 2011;25:3939–3945.
9. Takemura M, Ikebe T, Mayumi K, Nishioka T, Hori T. A novel liver retraction technique for lateral lobe of the liver during laparoscopic surgery using silicone disk. *J Laparoendosc Adv Surg Tech A* 2011;21:729–732.
10. Fan Y, Wu SD, Kong J, Su Y, Tian Y. Transumbilical single-incision laparoscopic fundoplication: A new technique for liver retraction using cyanoacrylate. *J Laparoendosc Adv Surg Tech A* 2013;23:356–360.
11. Yilmaz H, Alptekin H. Single-port laparoscopic Nissen fundoplication: A new method for retraction of the left lobe of the liver. *Surg Laparosc Endosc Percutan Tech* 2012;22:e265–e256.
12. Eyuboglu E, Ipek T, Atasoy D. Single-port laparoscopic floppy Nissen fundoplication: A novel technique with the aid of the Cerrahpasa retractor. *J Laparoendosc Adv Surg Tech A* 2012;22:173–175.
13. Hamzaoglu I, Karahasanoglu T, Aytac E, Karatas A, Baca B. Transumbilical totally laparoscopic single-port Nissen fundoplication: a new method of liver retraction: The Istanbul technique. *J Gastrointest Surg* 2010;14:1035–1039.
14. Pasenau J, Mamazza J, Schlachta CM, Seshadri PA, Poulin EC. Liver hematoma after laparoscopic Nissen fundoplication: A case report and review of retraction injuries. *Surg Laparosc Endosc Percutan Tech* 2000;10:178–181.

Address correspondence to:  
 Marcel Aufran C. Machado, MD  
 Rua Dona Adma Jafet 74, cj 102  
 São Paulo, Brazil

E-mail: dr@drmarcel.com.br