

LAPAROSCOPIC PANCREATIC RESECTION. FROM ENUCLEATION TO PANCREATODUODENECTOMY. 11-YEAR EXPERIENCE

Marcel Autran Cesar **MACHADO**¹, Rodrigo Cañada Trofo **SURJAN**¹, Suzan Menasce **GOLDMAN**², José Celso **ARDENGH**³ and Fábio Ferrari **MAKDISSI**¹

ABSTRACT - Context - Our experience with laparoscopic pancreatic resection began in 2001. During initial experience, laparoscopy was reserved for selected cases. With increasing experience more complex laparoscopic procedures such as central pancreatectomy and pancreatoduodenectomies were performed. **Objectives** - The aim of this paper is to review our personal experience with laparoscopic pancreatic resection over 11-year period. **Methods** - All patients who underwent laparoscopic pancreatic resection from 2001 through 2012 were reviewed. Preoperative data included age, gender, and indication for surgery. Intraoperative variables included operative time, bleeding, blood transfusion. Diagnosis, tumor size, margin status were determined from final pathology reports. **Results** - Since 2001, 96 patients underwent laparoscopic pancreatectomy. Median age was 55 years old. 60 patients were female and 36 male. Of these, 88 (91.6%) were performed totally laparoscopic; 4 (4.2%) needed hand-assistance, 1 robotic assistance. Three patients were converted. Four patients needed blood transfusion. Operative time varied according type of operation. Mortality was nil but morbidity was high, mainly due to pancreatic fistula (28.1%). Sixty-one patients underwent distal pancreatectomy, 18 underwent pancreatic enucleation, 7 pylorus-preserving pancreatoduodenectomies, 5 uncinata process resection, 3 central and 2 total pancreatectomies. **Conclusions** - Laparoscopic resection of the pancreas is a reality. Pancreas sparing techniques, such as enucleation, resection of uncinata process and central pancreatectomy, should be used to avoid exocrine and/or endocrine insufficiency that could be detrimental to the patient's quality of life. Laparoscopic pancreatoduodenectomy is a safe operation but should be performed in specialized centers by highly skilled laparoscopic surgeons.

HEADINGS - Pancreatectomy. Pancreaticoduodenectomy. Laparoscopy.

INTRODUCTION

Laparoscopy has been used routinely by general surgeons for the last two decades. However, laparoscopic pancreatic operations developed slowly, due to the anatomic complexity, retroperitoneal location, and high post-operative morbidity due mainly to the digestive enzyme-rich secretions it produces^(5, 6, 7, 11, 19). Nevertheless, laparoscopic pancreatic resection has been increasingly used for the last decade and more complex operations such as pancreaticoduodenectomy were being progressively added to the surgical armamentarium^(9, 16).

Our experience with laparoscopic pancreatic resection began in 2001⁽¹³⁾. During initial experience, laparoscopy was reserved for selected cases with benign or low grade neoplasms. Main procedures were laparoscopic enucleations and resection of distal pancreas. With increasing experience and

development of new instruments more complex laparoscopic procedures were performed such as total pancreatectomy, left pancreatectomy with spleen preservation, resection of uncinata process⁽¹⁵⁾ and pancreatoduodenectomies⁽¹⁶⁾. The aim of this paper was to review our experience with laparoscopic pancreatic resection over 11-year period.

METHODS

A retrospective review of a prospectively maintained database was performed. All patients who underwent laparoscopic pancreatic resection from 2001 through 2012 were identified. Descriptive data were collected. Preoperative variables included age, gender, and indication for surgery. Intraoperative variables included operative time, bleeding, blood transfusion. Diagnosis, tumor size, margin status were determined from final pathology reports. Pancreatic fistula was

¹ Hospital Sirio Libanês, SP, Brasil. ² Departamento de Diagnóstico por Imagem, Escola Paulista de Medicina da Universidade Federal de São Paulo (EPM-UNIFESP); ³ Departamento de Cirurgia e Anatomia, Faculdade de Medicina de Ribeirão Preto da Universidade de São Paulo (FMRP-USP), Ribeirão Preto, SP, Brasil. Correspondence: Marcel Autran C. Machado. Rua Dona Adma Jafet, 74 cj 102 - 01308-050 - São Paulo, SP, Brasil - E-mail: dr@drmarcel.com.br

assessed and graded according to the International Study Group on Pancreatic Fistula recommendations⁽³⁾.

Preoperative assessment

A variety of imaging modalities were used for assessing pancreatic lesions, including ultrasonography (US), computed tomography (CT), magnetic resonance imaging, endoscopic US. The use of relevant clinical information and key radiologic features was essential for confident lesion characterization and differentiation and therefore for surgical planning⁽¹⁾. Preoperative workup included MR and endoscopic US in the majority of patients (Figure 1).

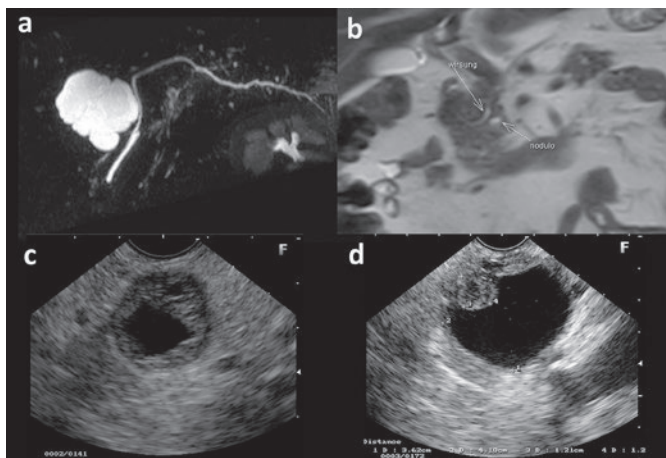


FIGURE 1. Preoperative imaging assessment

- Magnetic resonance cholangiopancreatography shows a large cystic tumor in the head of the pancreas. Relationship with main pancreatic duct is observed.
- Magnetic resonance imaging detected a small tumor and shows its proximity with the main pancreatic duct.
- Endoscopic ultrasound showed neuroendocrine cystic tumor of the neck of the pancreas. This patient underwent central pancreatectomy.
- Endoscopic ultrasound showing intraductal papillary mucinous tumor with a malignant tiny nodule in the uncinete process of the pancreas.

RESULTS

Since 2001, 96 patients underwent laparoscopic pancreatectomy. Median age was 55 years old (range 20-77 years). Sixty patients were female and 36 male. In 88 (91.6%) the procedures were performed totally by laparoscopy; 4 (4.2%) needed hand-assistance, 1 (1%) robotic assistance. Three (3.1%) patients were converted to laparotomy, two for bleeding and one for technical difficulties (portal vein invasion). Four (4.2%) patients needed blood transfusion. Operative time varied according the type of operation. Mortality was nil but morbidity was high, mainly due to pancreatic fistula (28.1%). However, most cases (85.2%) were grade A. Three patients needed readmission, one for incarcerated trocar hernia that was resolved surgically and two needed percutaneous drainage of peripancreatic collection. One patient needed late reoperation for persistent pancreatic fistula 6 months after initial operation.

Majority of patients underwent distal pancreatectomy with or without spleen preservation (Figure 2c), 18 underwent pancreatic enucleation (Figure 2a), 7 pylorus-preserving pancreatoduodenectomies (Figure 3), 2 pylorus-preserving total pancreatectomies (Figure 2d). Table 1 shows patient distribution according to the type of laparoscopic resection. Reconstruction of the pancreatic remnant after central resection (Figure 4) or after pancreatoduodenectomy (Figure 3), was performed with Roux-en-Y end-to-side pancreatojejunostomy. Reconstruction of the alimentary tract after pylorus preserving pancreatoduodenectomy was performed using double jejunal loop according published technique^(16, 17). Five

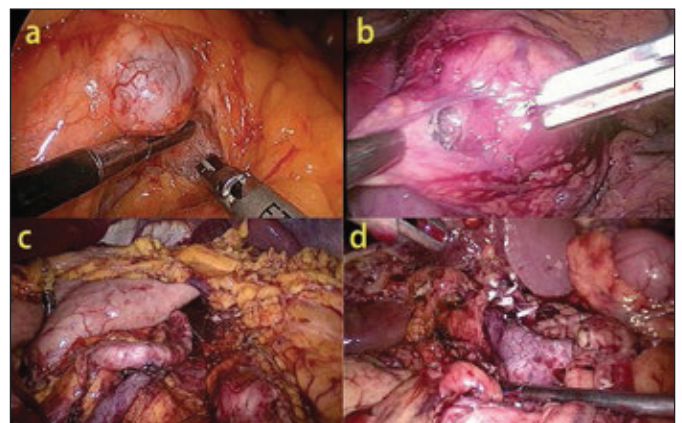


FIGURE 2. Laparoscopic pancreatic resections

- Intraoperative view of enucleation of a neuroendocrine tumor at the body of the pancreas.
- Intraoperative view of resection of the uncinete process of the pancreas containing a Frantz tumor.
- Overview after distal pancreatectomy with preservation of the splenic vessels and spleen.
- Intraoperative view after pylorus-preserving total pancreatectomy with preservation of the splenic vessels and spleen.

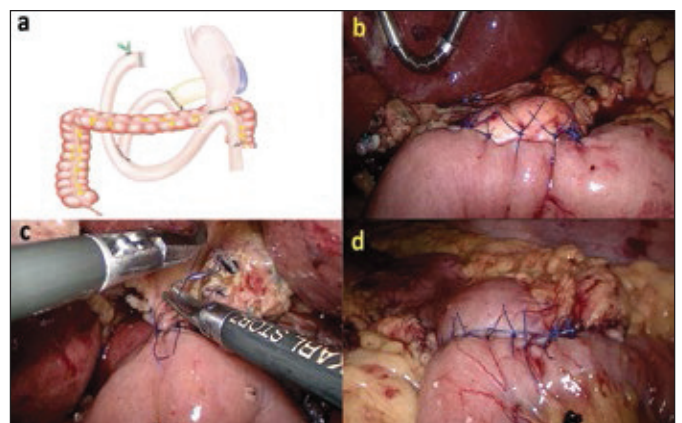


FIGURE 3. Laparoscopic pylorus-preserving pancreato-duodenectomy with double jejunal loop reconstruction

- Schematic drawing of the technique for reconstruction after pylorus-preserving laparoscopic pancreatoduodenectomy.
- Intraoperative view of end-to-side pancreato-jejunostomy.
- Intraoperative view of end-to-side hepatico-jejunostomy.
- Intraoperative view of end-to-side duodeno-jejunostomy.

TABLE 1. Patient distribution according type of laparoscopic pancreatic resection

Type	Patients n.	%
Distal pancreatectomy (DP)	49	51,0
Enucleation	18	18,8
Spleen-preserving DP	12	12,5
Pancreatoduodenectomy	7	7,3
Uncinate process resection	5	5,2
Central pancreatectomy	3	3,1
Total pancreatectomy	2	2,1
Total	96	100,0

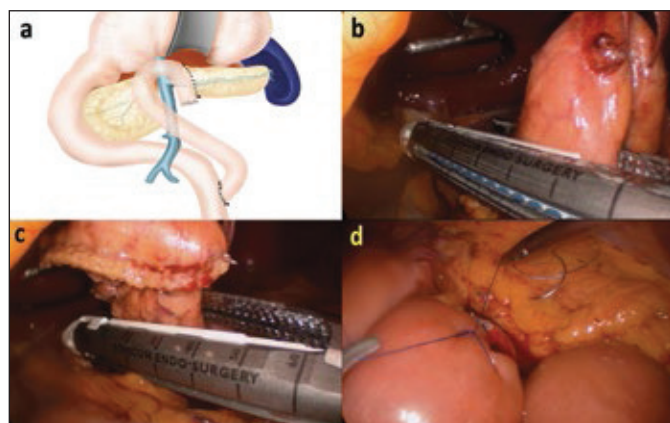


FIGURE 4. Laparoscopic central pancreatectomy with Roux-en-Y pancreateo-jejunostomy
 a) Schematic drawing of the technique used for central pancreatectomy and reconstruction.
 b) Neck of the pancreas is divided with stapler near head of the pancreas.
 c) Pancreas is divided with stapler, removing pancreatic neck.
 d) Intraoperative view of end-to-side pancreateo-jejunostomy.

patients underwent laparoscopic resection of the uncinate process (Figure 2b). There was a progressive number of laparoscopic pancreatectomy along the period of study towards less patient selection (inclusion of malignancy) and more proximal resections (pancreatoduodenectomy). Some patients with malignant tumors with known portal vein proximity or lateral invasion were operated using hand assistance (Figure 5).

Most patients underwent laparoscopic pancreas resection for benign or low grade neoplasms. Thirty-six (37.5%) patients were operated on for pancreatic cystadenomas, 28 for neuroendocrine tumors (all of them with low grade – G1), 19 for intraductal papillary mucinous neoplasm (IPMN). One patient was operated on for pancreatic metastasis from renal cancer and one for chronic pancreatitis. Table 2 shows patient distribution according indication of laparoscopic pancreatic resection.

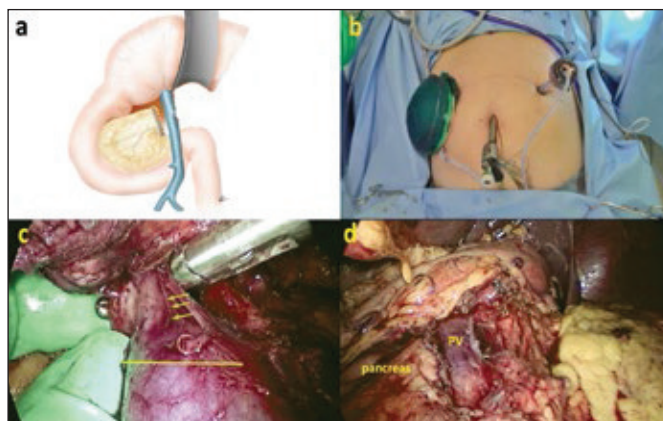


FIGURE 5. Laparoscopic hand-assisted subtotal pancreatectomy with partial resection of the spleno-mesenteric junction
 a) Schematic drawing of the technique used for subtotal pancreatectomy.
 b) Intraoperative view of trocar positions and hand port.
 c) Spleno-mesenteric venous junction is invaded by the tumor (small arrows). Future line for section removing part of portal vein (lateral resection) is show (continuous line).
 d) Final view after subtotal pancreatectomy. Note that part of the pancreatic head was removed. Portal vein (PV) was divided with stapler.

TABLE 2. Patient distribution according indication for laparoscopic pancreatic resection

Disease	Patients n.	%
Cystadenomas	36	37,5
NET	28	29,2
IPMN	19	19,8
Adenocarcinoma	9	9,4
Frantz tumor	2	2,1
Other	2	2,1
Total	96	100,0

NET: Neuroendocrine tumor; IPMN: Intraductal papillary mucinous neoplasm

DISCUSSION

Laparoscopic pancreatic surgery has experienced significant development in the last few years. The majority of procedures are left pancreatectomy and enucleations^(5, 6, 7, 10, 11, 19). More complex pancreatic resections such as pancreatoduodenectomies^(2, 16, 18), resections of uncinate process of the pancreas^(15, 21) and central pancreatectomies⁽²⁰⁾ were performed routinely in very few centers.

Patient selection for laparoscopic pancreatic resection includes consideration of comorbidities, tumor size and location, and presumed pathology. As experience with laparoscopy has increased, selection criteria have broadened, with inclusion of patients with increased comorbidities and larger, more medial tumors and more proximal tumor location^(7, 11, 16). Despite a shift in patient selection to sicker patients with more proximal tumors, similar perioperative outcomes were achieved^(11, 19). Our experience with laparo-

scopic pancreatic resections began in 2001 with distal pancreatectomy⁽¹³⁾. Similarly as occurred with other authors, improvement of our expertise in advanced laparoscopic surgery has allowed us to perform more complex operations such as central pancreatectomies, pancreatoduodenectomy and resection of uncinate process and in patients with comorbidities and with overt malignant neoplasms.

Laparoscopy has become a less invasive alternative to pancreatic surgery, but recent imaging advances resulted in proper preoperative anatomic evaluation that was essential for surgical planning. The ability of appropriate identification and location of the lesion, distance from the main pancreatic duct and relationship to adjacent organs and vessels made the procedure safer. Magnetic resonance imaging using equipment with higher magnetic fields and gradient greatly improved the quality and detail of the images^(12, 22). Accurate diagnosis can be challenging, and use of a multimodality approach, using magnetic resonance cholangiopancreatography combines the strengths of individual imaging modalities and has a synergistic effect in improving diagnostic yield. Such an approach is of special importance in equivocal or complex cases^(12, 22).

Endoscopic ultrasound has also been included in our preoperative assessment in the more recent cases. Information such as major vessel encasement and invasion of peripancreatic adjacent tissue were determinant to contraindicate minimally invasive technique as an oncologic operation. Other information, such as study of pancreatic cyst liquid, may contraindicate useless operation in cases of serous cystadenoma or be diagnostic in cases of mucinous or malignant cystic tumors. Biopsy of the pancreatic lesion may also be essential in difficult cases to confirm neoplastic origin of some unspecific pancreatic tumors⁽²²⁾.

Laparoscopic distal pancreatectomy with or without spleen preservation has become a gold standard in the last years. Based on the available data, laparoscopic distal pancreatectomy have adequate safety profiles, equivalent or better perioperative outcomes, and noninferior oncologic outcomes^(11, 19). The same is true for laparoscopic enucleations⁽⁵⁾.

In special cases when tumor is located in the neck of the pancreas, the ideal operation is central pancreatectomy. Considering long-term functional results, central pancreatectomy is an effective technique to preserve pancreatic function^(4, 23). In a comparative study, the outcomes after central pancreatectomy (100 cases) were compared with a control group (45 patients) that underwent extended left pancreatectomy for neoplasms in the mid pancreas⁽⁴⁾. After a median follow-up of 54 months, the incidences of endocrine and exocrine insufficiency after central pancreatectomy were 4% and 5%, respectively, compared to 38% and 15.6% in patients who underwent extended distal pancreatectomy. Laparoscopic resection of the neck of the pancreas or of any segment in the middle of the pancreas is not difficult. However it entails reconstruction of the main pancreatic duct which may be difficult and sometimes hazardous laparoscopically⁽²⁰⁾. The popularity of laparoscopic left pancreatectomy certainly

reduced the number of patients undergoing laparoscopic central pancreatectomy. However this is made at expense of endocrine and exocrine deficiency that extended left pancreatectomy may produce. For benign or low grade neoplasms, left pancreatectomy may remove too much functioning pancreatic parenchyma. Due to this fact, in cases with tumor in the neck of the pancreas our procedure of choice is central pancreatectomy with Roux-en-Y pancreatojejunostomy.

Another important pancreas sparing technique is resection of uncinate process of the pancreas. Although it is a highly anatomic technique there are very few papers dealing with laparoscopic resection of the uncinate process. We were the world's first to perform this complex operation⁽¹⁵⁾ laparoscopically and we were followed by other authors with elegant modification of the original technique⁽²¹⁾. It can and should be used in cases where the tumor is located in the uncinate process of the pancreas and where the main duct is at a safe distance from the tumor. In this setting it is essential to preoperatively evaluate the patient with magnetic resonance cholangiopancreatography and endoscopic ultrasound. These imaging findings should be further confirmed with intraoperative ultrasound. If this workup is correctly performed, we can use this technique instead of pancreatoduodenectomy in patients with benign or low grade malignant neoplasms.

Laparoscopic pancreatoduodenectomy was first performed in 1992⁽⁸⁾ but for a long period of time has been rarely performed and by a reduced number of surgeons given the difficulty level of the procedure. However, there is a growing interest in this type of surgery lately, and the number of procedures is rapidly increasing. In a recent review of all published cases, 285 cases were found⁽⁹⁾. According to this review, overall mortality was 2%, and the morbidity rate was 48%. Pancreatic fistulas from pancreatic anastomosis are the most common factor responsible for the high morbidity and mortality after both open and laparoscopic pancreatoduodenectomy. Due to this fact we idealize the use of a double jejunal loop reconstruction to avoid or minimize the effects of pancreatic fistula, as occurred in open three decades ago^(16, 17).

The use of hand-assistance was necessary in malignant cases where difficulty of dissection of the spleno-mesenteric junctions was expected bases upon preoperative imaging (Figure 5). This was a previous contraindication for the laparoscopic approach but the development of hand port devices made this operation possible. Hand assistance was also used as a step before a conversion in cases of technical difficulties.

Another recent point of discussion is the use of robotic assistance in laparoscopic pancreatic resection. Although we have performed the first robotic pancreatectomy in Latin America⁽¹⁴⁾ in 2008, we did not find any advantage over standard laparoscopic pancreatectomy. We believe that given the higher costs this aid should be reserved for more complex operations.

Laparoscopic resection of the pancreas is a reality. However, no adaptation of laparoscopic technique should be done at expense of surgical and oncologic principles. Adequate margins of resection and lymph node harvest should be a priority in malignant cases. Pancreas sparing techniques,

such as enucleation, resection of uncinate process and central pancreatectomy, should be used to avoid exocrine and/or endocrine insufficiency that could be detrimental to the patient's quality of life, especially for benign or low-grade malignant neoplasm.

CONCLUSION

Laparoscopic pancreatic resection is a safe operation but should be performed in specialized centers by highly skilled laparoscopic surgeons.

Machado MAC, Surjan RCT, Goldman SM, Ardengh JC, Makdissi FF. Pancreatectomia laparoscópica. Da enucleação à duodenopancreatectomia. 11 anos de experiência. *Arq Gastroenterol.* 2013;50(3):214-8.

RESUMO - Contexto - Nossa experiência com ressecção pancreática laparoscópica começou em 2001. No início, a laparoscopia esteve reservada para casos selecionados. Com o aumento da experiência, procedimentos mais complexos, como pancreatectomia central e pancreato duodenectomia, foram realizadas por laparoscopia. **Objetivos** - O objetivo deste trabalho foi rever a experiência de 11 anos com ressecção pancreática laparoscópica. **Métodos** - Foram analisados todos os pacientes submetidos à ressecção pancreática laparoscópica entre 2001 e 2012 e incluídos dados pré-operatórios como idade, sexo e indicação cirúrgica, bem como variáveis intra-operatórias como o tempo operatório, o sangramento e transfusão. O diagnóstico final, o tamanho e a margem foram determinados a partir dos laudos anatomopatológicos. **Resultados** - Desde 2001, 96 pacientes foram submetidos à pancreatectomia laparoscópica. A média de idade foi de 55 anos. Foram 60 homens e 36 mulheres. Oitenta e oito (91,6%) operações foram realizadas por laparoscopia e quatro (4,2%) necessitaram de auxílio da mão e uma robótica. Três pacientes foram convertidos. Quatro necessitaram de transfusão de sangue. O tempo operatório variou de acordo com tipo de operação. A mortalidade foi nula, mas a morbidade foi alta, principalmente devido à fistulas pancreáticas (28,1%). Sessenta e um pacientes foram submetidos à pancreatectomia distal, 18 à enucleação do pâncreas, 7 à duodenopancreatectomia com preservação de piloro, 5 à ressecção do processo uncinado, 3 centrais e duas pancreatectomias totais. **Conclusão** - Ressecção laparoscópica do pâncreas é uma realidade. Técnicas que preservam o parênquima, como enucleação, ressecção do processo uncinado e pancreatectomia central, devem ser usadas para evitar insuficiência exócrina e/ou endócrina. Duodenopancreatectomia laparoscópica é operação segura, mas deve ser realizada em centros especializados e por cirurgiões laparoscópicos adequadamente treinados.

DESCRITORES – Pancreatectomia. Pancreaticoduodenectomia. Laparoscopia.

REFERENCES

- Ardengh JC, Goldman SM, Lima-Filho ER. Current role of imaging methods in the diagnosis of cystic solid pancreas neoplasms. *Rev Col Bras Cir.* 2011;38:133-8.
- Asbun HJ, Stauffer JA. Laparoscopic vs open pancreaticoduodenectomy: overall outcomes and severity of complications using the Accordion Severity Grading System. *J Am Coll Surg.* 2012;215:810-9.
- Bassi C, Dervenis C, Butturini G, Fingerhut A, Yeo C, Izbicki J, Neoptolemos J, Sarr M, Traverso W, Buchler M; International Study Group on Pancreatic Fistula Definition. Postoperative pancreatic fistula: an international study group (ISGPF) definition. *Surgery.* 2005;138:8-13.
- Crippa S, Bassi C, Warshaw AL, Falconi M, Partelli S, Thayer SP, Pederzoli P, Fernández-del Castillo C. Middle pancreatectomy: indications, short- and long-term operative outcomes. *Ann Surg.* 2007;246:69-76.
- Dedieu A, Rault A, Collet D, Masson B, Sa Cunha A. Laparoscopic enucleation of pancreatic neoplasm. *Surg Endosc.* 2011;25:572-6.
- Fernández-Cruz L, Cosa R, Blanco L, Levi S, López-Boado MA, Navarro S. Curative laparoscopic resection for pancreatic neoplasms: a critical analysis from a single institution. *J Gastrointest Surg.* 2007;11:1607-21.
- Fisher SB, Kooby DA. Laparoscopic pancreatectomy for malignancy. *J Surg Oncol.* 2013;107:39-50.
- Gagner M, Pomp A. Laparoscopic pylorus-preserving pancreatoduodenectomy. *Surg Endosc.* 1994;8:408-410.
- Gumbs AA, Rodriguez Rivera AM, Milone L, Hoffman JP. Laparoscopic pancreatoduodenectomy: a review of 285 published cases. *Ann Surg Oncol.* 2011;18:1335-41.
- Jayaraman S, Gonen M, Brennan MF, D'Angelica MI, DeMatteo RP, Fong Y, Jarnagin WR, Allen PJ. Laparoscopic distal pancreatectomy: evolution of a technique at a single institution. *J Am Coll Surg.* 2010;211:503-9.
- Kneuert PJ, Patel SH, Chu CK, Fisher SB, Maithel SK, Sarmiento JM, Weber SM, Staley CA, Kooby DA. Laparoscopic distal pancreatectomy: trends and lessons learned through an 11-year experience. *J Am Coll Surg.* 2012;215:167-76.
- Low G, Panu G, Millon N, Leen E. Multimodality imaging of neoplastic and nonneoplastic solid lesions of the pancreas. *Radiographics.* 2011;31:4 993-1015.
- Machado MA, Canedo LF, Herman P, Montagnini AL, Sallum RA, Machado MC. Laparoscopic distal pancreatectomy for pancreatic cystadenomas. *Arq Gastroenterol.* 2005;42:157-160.
- Machado MA, Makdissi FF, Surjan RC, Abdalla RZ. Robotic resection of intraductal neoplasm of the pancreas. *J Laparoendosc Adv Surg Tech A.* 2009;19:771-5.
- Machado MA, Makdissi FF, Surjan RC, Machado MC. Laparoscopic resection of uncinate process of the pancreas. *Surg Endosc.* 2009;23:1391-2.
- Machado MA, Makdissi FF, Surjan RC, Machado MC. Laparoscopic Pylorus-Preserving Pancreatoduodenectomy with Double Jejunal Loop Reconstruction: An Old Trick for a New Dog. *J Laparoendosc Adv Surg Tech A.* 2013;23:146-9.
- Machado MC, da Cunha JE, Bacchella T, Bove P. A modified technique for the reconstruction of the alimentary tract after pancreatoduodenectomy. *Surg Gynecol Obstet.* 1976;143:271-2.
- Palanivelu C, Rajan PS, Rangarajan M, Vaithiswaran V, Senthilnathan P, Parthasarathi R, Praveen Raj P. Evolution in techniques of laparoscopic pancreaticoduodenectomy: a decade long experience from a tertiary center. *J Hepatobiliary Pancreat Surg.* 2009;16:731-40.
- Pericleous S, Middleton N, McKay SC, Bowers KA, Hutchins RR. Systematic review and meta-analysis of case-matched studies comparing open and laparoscopic distal pancreatectomy: is it a safe procedure? *Pancreas.* 2012;41:993-1000.
- Rotellar F, Pardo F, Montiel C, Benito A, Regueira FM, Poveda I, Martí-Cruchaga P, Cienfuegos JA. Totally laparoscopic Roux-en-Y duct-to-mucosa pancreaticojejunostomy after middle pancreatectomy: a consecutive nine-case series at a single institution. *Ann Surg.* 2008;247:938-44.
- Rotellar F, Pardo F, Benito A, Martí-Cruchaga P, Zozaya G, Cienfuegos JA. Laparoscopic resection of the uncinate process of the pancreas: the inframesocolic approach and hanging maneuver of the mesenteric root. *Surg Endosc.* 2011;25:3426-7.
- Schraibman V, Goldman SM, Ardengh JC, Goldenberg A, Lobo E, Linhares MM, Gonzales AM, Abdala N, Abud TG, Ajzen SA, Jackowsky A, Szejnfeld J. New trends in diffusion-weighted magnetic resonance imaging as a tool in differentiation of serous cystadenoma and mucinous cystic tumor: a prospective study. *Pancreatol.* 2011;11:43-51.
- Warshaw AL, Rattner DW, Fernández-del Castillo C, Z'graggen K. Middle segment pancreatectomy. A novel technique for conserving pancreatic tissue. *Arch Surg.* 1998;133:327-330.

Received 4/3/2013.
Accepted 13/5/2013.